



AT THE FOREFRONT

**UChicago  
Medicine**

## **ENDORAMA**

# **A Twenty Two Year Old with a Lateral Neck Mass**

**Lee Stratton, MD**

**Feb 18, 2021**

Dr. Stratton does not have any relevant financial relationships with any commercial interests.

# Learning Objectives

- Review of lateral aberrant thyroid
- Other potential locations of ectopic thyroid
- Differentiating ectopic thyroid vs atypical presentations of thyroid cancer

THE UNIVERSITY OF  
CHICAGO  
MEDICINE

# Case Description

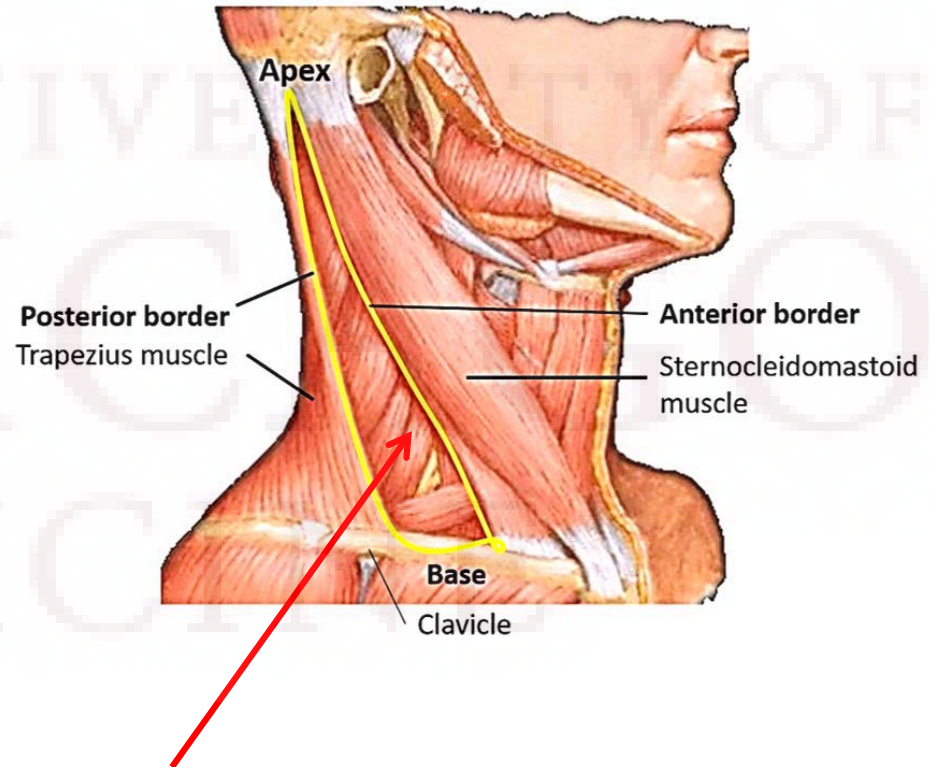
- 7/2020: 21 y/o M presents to PCP with a self-palpated right lateral neck mass. No changes in speech
- PMH/PSH: COVID+ earlier in July, minimally symptomatic
- FH: negative for endocrine disorders
- SH: college student in Ohio, family from Chicagoland

# Case Description

- Exam: Right posterior 1 cm neck mass - Right Posterior Triangle (lateral / posterior neck)

More palpable when he'd turn head to the left

Otherwise normal exam



# Differential Diagnosis



THE UNIVERSITY OF  
CHICAGO  
MEDICINE



AT THE FOREFRONT  
**UChicago**  
**Medicine**

# Initial Workup

- CT Neck: left level V 1.5cm lymph node
- Excisional biopsy:
  - Right neck mass:
    - Lymph node with capsular/subcapsular thyroid epithelium
    - The epithelium is positive for TTF-1 and thyroglobulin. GATA3 is negative. Ki-67 shows less than 5% positivity.
    - The above immunoprofile, along with the cytologic features, are most compatible with a metastatic papillary thyroid carcinoma.

# Further Workup

- Thyroid US

Left: Enlarged left submandibular lymph node with cortical thickening measuring 2.5 cm x 1.3 cm. Enlarged left level 2 jugular chain lymph node measuring 2.3 cm x 1 cm. Enlarged left level 3 jugular chain lymph node measuring 2.1 cm x 1 cm. Few additional small left level 4 jugular chain and left level 5 posterior cervical triangle lymph nodes measuring 5 mm and less in short axis.

Right: Multiple small right level 2, level 3, level 4, and posterior cervical triangle lymph nodes measuring 7 mm and less in short axis.

Thyroid: No sonographically demonstrable thyroid mass. Single three millimeter calcification in posterior portion of right thyroid, no definitive nodules.

# Recap

- Diagnosis of PTC in right level V
- No definitive thyroid nodule seen

UNIVERSITY OF  
CHICAGO  
MEDICINE



AT THE FOREFRONT

**UChicago**  
**Medicine**



# Management

Metastatic thyroid cancer vs Ectopic thyroid tissue in a lateral neck node

Thyroid cancer with no primary on imaging

Ectopic thyroid tissue in a reactive LN

- FNA of macrocalcification: 3cm deep, technically difficult, high chance of potential false negative
- Not enough tissue for molecular testing
- Observation vs surgical resection

# Lateral Aberrant Thyroid

- Termed in 1779, term narrowed in early 20<sup>th</sup> century, fallen out of favor in 21<sup>st</sup> century due to lack of precision
- Collectively includes thyroid tissue lateral to the internal jugular veins
  - Malignant: nodal mets, branchial clefts with thyroid cancer
  - Benign: parasitic thyroid nodule, displaced thyroid tissue post-op, true ectopic thyroid

# Parasitic Thyroid Nodules

- Peripheral nodule of goiter separated from thyroid tissue, most often about 1cm from thyroid
- Synonyms: sequestered goiter, detached, or accessory thyroid nodule
- Incidence: female to male ratio 4:1, median age of 51
- Most common with MNG or Hashimoto's thyroiditis
- Mechanism: ablation of existing tissue or shearing from movement of muscles

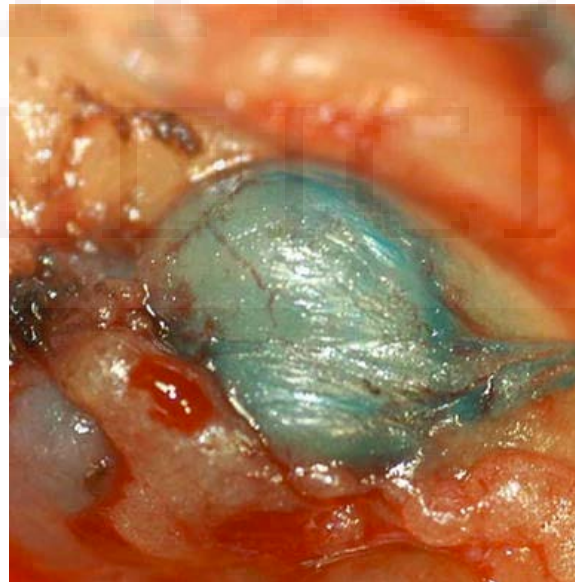
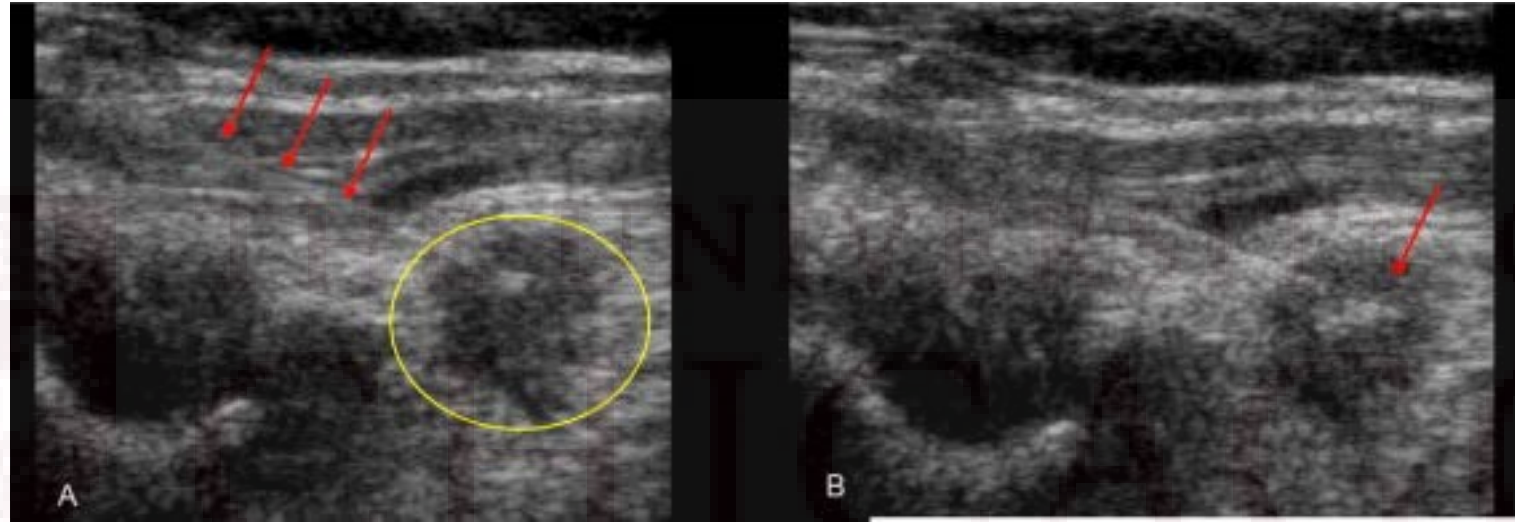
# Ectopic Thyroid

- Synonyms: heterotopic, accessory, choristoma
  - Wolfer gland (cervical accessory thyroid)
  - Struma cordis (cardiac thyroid)
- Total ectopia vs accessory
- Single vs multiple
- Gross vs microscopic
- Midline vs lateral

# Surgical Evaluation

- Slides evaluated here by our pathology dept: metastatic PTC (3mm focus in 1/1 LN). Comments that there was a cystic component
- LN Mapping US: small, ill-defined hypoechoic posterior right-sided nodule
- OR: Total thyroidectomy, right central neck dissection, right modified radical neck dissection with methylene blue injection

# Methylene Blue Injection



# Surgical Path

- A. Right level 3 lymph nodes; dissection:
  - Twelve lymph nodes, negative for carcinoma (0/12).
- B. Right level 4 lymph nodes; dissection:
  - Metastatic papillary thyroid carcinoma in one of eight lymph nodes (1/8), 0.7 cm, no extranodal extension.
- C. Right level 2 lymph nodes; dissection:
  - Seven lymph nodes, negative for carcinoma (0/7).
- D. Right level 5 lymph nodes; dissection:
  - Two lymph nodes, negative for carcinoma (0/2).
- E. Right paratracheal & pretracheal level 6 lymph nodes; dissection:
  - Metastatic papillary thyroid carcinoma in four lymph nodes (4/4), 0.3 cm, no extranodal extension.
- F. Thyroid gland; total thyroidectomy:
  - Papillary thyroid carcinoma (0.5 cm, right lobe)

type

Angioinvasion: Not identified

Lymphatic Invasion: PRESENT

Perineural Invasion: Not identified

Extrathyroidal Extension: PRESENT into fibroadipose tissue only

Margins: Uninvolved by carcinoma by <0.1 cm

Regional Lymph Nodes:

Total Number involved: 5/ Number examined: 33

- Level VI Right 4/4

- Level II: Right 0/7

- Level III: Right 0/ 12

- Level IV: Right 1 /8

- Level V: Right 0/2

Largest metastatic focus: 0.7 cm in Right Level IV

Extranodal Extension: Not identified

BRAF V600E positive

AJCC 8th Edition Pathologic TNM Staging: pT1a, N1b

Histologic Type: Papillary thyroid carcinoma, classic



**UChicago**  
**Medicine**

# Ongoing Care

- Returning to college next week
- Following up with his endocrinologist for consideration of RAI
- Thyroid function labs, thyroglobulin in 4 weeks




# Atypical Presentations of Thyroid Cancer

- Likelihood of malignancy > true ectopic lateral thyroid tissue
- Case reports of no primary found on surgical path
- Superior pole cancers

## ORIGINAL ARTICLE

# Features of papillary thyroid microcarcinoma associated with lateral cervical lymph node metastasis

Min Ji Jeon<sup>\*,a</sup> , Mi Sun Chung<sup>†,a</sup>, Hyemi Kwon<sup>\*</sup>, Mijin Kim<sup>\*</sup>, Suyeon Park<sup>\*</sup>, Jung Hwan Baekt, Dong Eun Song<sup>‡</sup>, Tae-Yon Sung<sup>§</sup>, Suck Joon Hong<sup>§</sup>, Tae Yong Kim<sup>\*</sup>, Won Bae Kim<sup>\*</sup>, Young Kee Shong<sup>\*</sup>, Jeong Hyun Leet and Won Gu Kim<sup>\*</sup>

<sup>\*</sup>Department of Internal Medicine, Asan Medical Center, University of Ulsan College of Medicine, <sup>†</sup>Department of Radiology and Research Institute of Radiology, Asan Medical Center, University of Ulsan College of Medicine, <sup>‡</sup>Department of Pathology, Asan Medical Center, University of Ulsan College of Medicine, and <sup>§</sup>Department of Surgery, Asan Medical Center, University of Ulsan College of Medicine, Seoul, Korea

	Univariate analysis		Multivariate analysis	
	OR (95% CI)	P-value	OR (95% CI)	P-value
Young age (<50 years)	1.91 (1.28–2.85)	0.002	1.86 (1.20–2.90)	0.005
Male sex	2.27 (1.36–3.89)	0.002	2.97 (1.66–5.44)	<0.001
Location in upper lobe	2.83 (1.82–4.45)	<0.001	2.67 (1.66–4.36)	<0.001
Subcapsular location	2.84 (1.84–4.46)	<0.001	2.97 (1.84–4.87)	<0.001
Marked hypo-echogenicity	1.12 (0.77–1.82)	0.449		
Spiculated margin	0.95 (0.62–1.55)	0.822		
Taller than wide shape	0.96 (0.59–1.56)	0.864		
Microcalcification	2.45 (1.64–3.69)	<0.001	2.43 (1.57–3.79)	<0.001

OR, odds ratio; CI, confidence interval.

# Predictors for central lymph node metastases in CNO papillary thyroid microcarcinoma (mPTC): A retrospective analysis of 1304 cases

Qiang Zhang <sup>a,b</sup>, Zhengmin Wang <sup>a</sup>, Xianying Meng <sup>a</sup>,  
Quan-Yang Duh <sup>b,\*\*,c</sup>, Guang Chen <sup>a,\*,c</sup>

Table 3 Multivariate analysis of risk factors of CLNM in cN0 mPTC patients.

Variables	Odds ratio	95%CI	<i>p</i> Value
Age ( $\leq 45$ years)	2.050	1.583, 2.654	$p < 0.01$
Gender (male)	1.935	1.376, 2.722	$p < 0.01$
Size ( $>0.5$ cm)	1.873	1.381, 2.539	$p < 0.01$
Bilaterality	1.857	1.243, 4.564	$p < 0.01$
Capsular invasion	1.493	1.087, 2.050	$p = 0.013$

# Questions

