



THE UNIVERSITY OF
CHILDREN
MEDICINE

62 y.o. female with
hirsutism

HPI

- ▶ 62 y.o. female who has been following in the clinic for postsurgical hypothyroidism, pituitary microadenoma on routine f/u visit noted with significant hirsutism

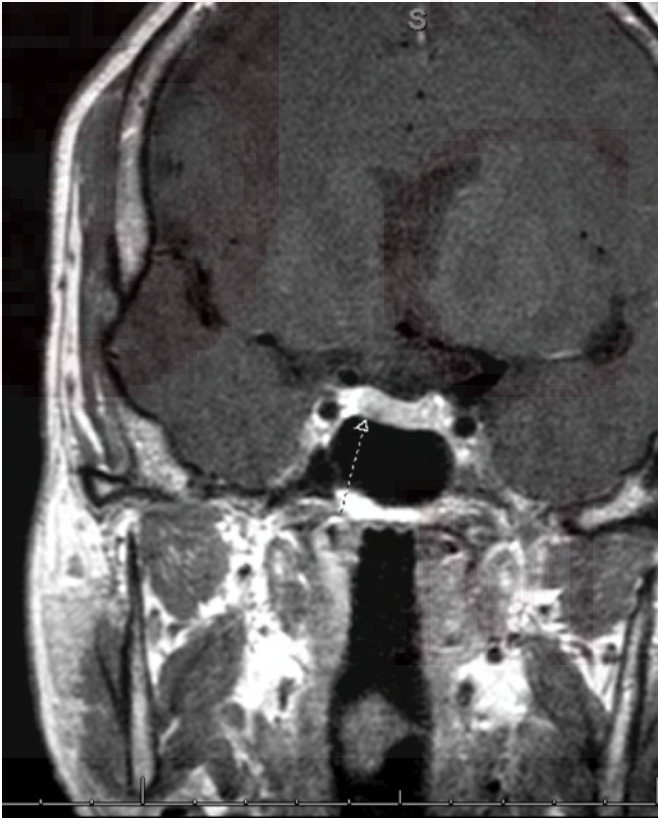
HPI

- ▶ Noted new facial hair growth 1-2 years ago accelerated over last 3-6 months
- ▶ Now requiring weekly waxing
- ▶ Denies significant worsening hair growth in other areas (thighs, pubic, arms, breast/chest etc.), maybe some over lower legs and perineal area
- ▶ Deepening of the voice noted years ago (after thyroidectomy 2014) and was investigated, no change since
- ▶ Denies thinning of scalp hair
- ▶ More oily skin, + acne
- ▶ Clitoral enlargement noted ~2 years ago when became sexually active again
- ▶ No changes in sex drive

Other pertinent history

- ▶ Menstrual periods regular, however heavy
- ▶ Last MP 12/1997
- ▶ Hysterectomy 3/1998 due to excessive bleeding
- ▶ G1P0 (abortion) did not try more
- ▶ In her 30s was told she has ovarian cysts at 2 different occasions

Past medical history:



- ▶ **Hypothyroidism:** diagnosed with multinodular goiter in 2005. She is s/p total thyroidectomy with Dr. Angelos on 4/1/14. Benign pathology. LT4 was tapered down from 137 mcg post op to 88 mcg recently after presentation with thyrotoxicosis

- ▶ **Pituitary microadenoma:** initially noted at 6 mm in 2005 with no significant changes until 2015 when it was measured at 3 mm.

- ▶ repeat MRI 2017: punctate T2 hyperintensity within the left aspect of the anterior pituitary gland, measuring 3 x 3 mm. also possible relative hypoenhancement along the inferior aspect of the right lateral anterior gland measuring 2-3. there is a slightly heterogeneous enhancement pattern of the gland.

she had normal ACTH stimulation test, normal FSH, IGF-1, and prolactin. normal visual field testing in November 2013. Her prolactin was mildly elevated in 2005. She was never treated with a dopamine agonist

PMHx

Migraine HA

Secondary hyperparathyroidism

?RA on steroids/methotrexate/Plaquenil at some point

Depression/anxiety

Rosacea/acne vulgaris

CKD III

Sx: thyroidectomy 2014, hysterectomy 3/1998



Family history

- ▶ Mother with Hx of migraine, depression, DM II, pancreatic cancer metastasized to Ovaries
- ▶ Father: prostate CA, asthma
- ▶ PGM: pancreatic Ca
- ▶ Breast Ca in multiple fam members maternal side

ROS

- ▶ Constitutional: no fever/chills, night sweats, denies weight loss, + **fatigue**, + **anxiety**
- ▶ HEENT: no blurred or double vision, no dysphagia, + **hoarseness**
- ▶ RESP: no dyspnea, no cough or increased WOB
- ▶ CV: denies CP/palpitations, LE edema
- ▶ GI: no abdominal pain/N/V/diarrhea, no constipation
- ▶ GU: no urinary symptoms, + **vaginal dryness** (Tx with estrogen pills)
- ▶ MSK: + joint pain (chronic OA)
- ▶ Neuro: + **HAs**, no paresthesia's, no weakness
- ▶ Endo: no cold/heat intolerance, + **oily skin**, no hair loss
- ▶ Psych: + anxiety/depression, not suicidal

Physical exam

- ▶ Vital signs: Blood pressure 132/84, pulse 91, height 177.8 cm (5' 10"), weight 89.6 kg (197 lb 9.6 oz), BMI 28.4
- ▶ Const: NAD
- ▶ Generally: a well-appearing female in no acute distress.
- ▶ Neck - thyroidectomy scar
- ▶ Pulm - CTAB
- ▶ CV - no LEE
- ▶ Neuro - non focal, Axox3
- ▶ MuscSkelet - nl ROM
- ▶ GI - soft abdomen, not distended
- ▶ Skin - coarse hair chin and sideburns, acne




medications

- ▶ albuterol, mometasone, singulair, Flonase
- ▶ azelaic acid (AZELEX) 20 % Top cream
- ▶ cetirizine HCl, fexofenadine HCl
- ▶ chlorthalidone (HYGROTON) 25 mg Oral tablet
- ▶ clindamycin (CLEOCIN-T) 1 % Top topical gel,
topical metronidazole, econazole, sulfacetamide
Na-sulf
- ▶ clonazepam 0.5 mg Oral tablet
- ▶ cyclobenzaprine (FLEXERIL) 10 mg Oral tablet .
- ▶ escitalopram oxalate (LEXAPRO) 20 mg Oral
- ▶ estradiol 10 mcg VAGINAL tablet
- ▶ levothyroxine 88 mcg Oral tablet
- ▶ omeprazole (PRILOSEC), Zantac
- ▶ tramadol (ULTRAM) 50 mg Oral tablet

Thoughts on d/d and
workup?



Lab

	9/23/2019 1541
ENDOCRINOLOGY	
ACTH	
BHCG, Plasma, Quant.	1.4 *
Cortisol	5.9 *
Estradiol (Endo Lab)	
FSH	48.0 *
LH	43.6 *
Prolactin	
Prolactin	22.70
SMC/IGF1 Stim Panel	
Te Binding Globulin	84
Calculated Free Te...	34 *
Total Testosterone	217 ▲
Test Information	<i>The Total Test... *</i>
FSH	
ACTH	25.9
DHEA-S	35.7
IGF1 LC MS	

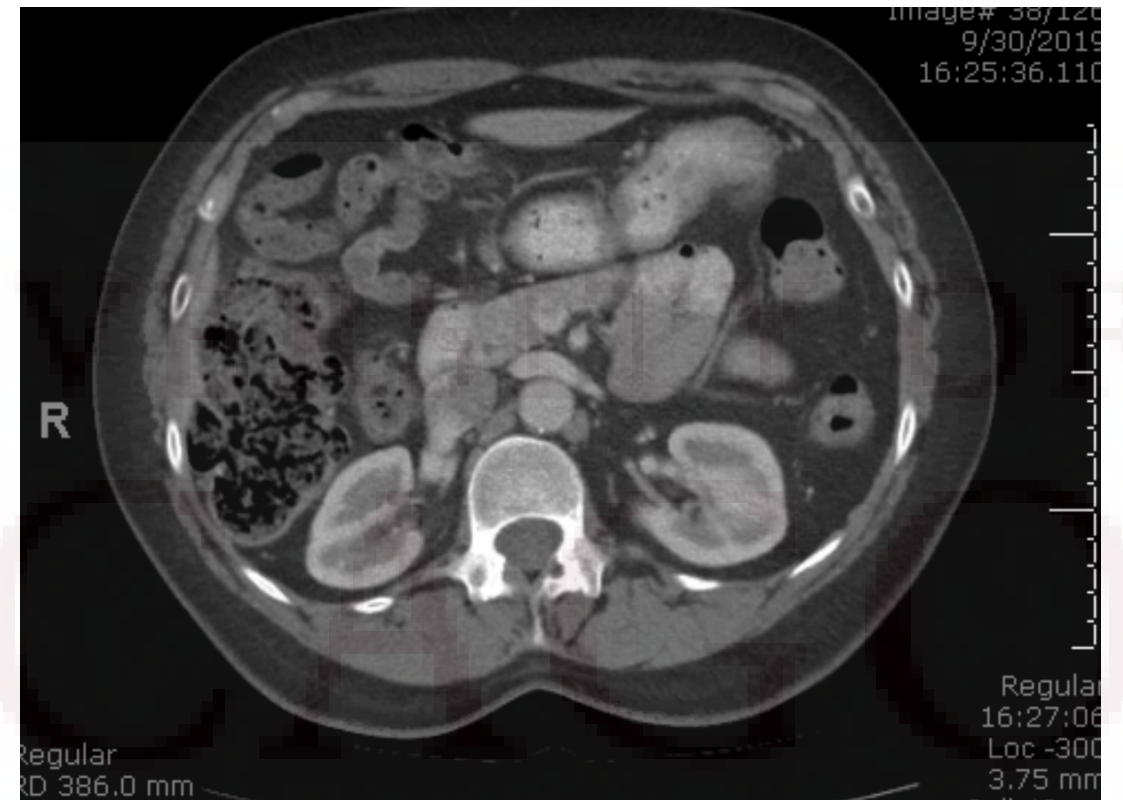
FSH 42.2 (20-135)

Component	Value	Ref Range & Units
IGF1 LC MS	98	35 - 201 ng/mL
IGF1 Z SCORE	0.13	NEG 2.0 - +2.0

	9/23/2019 1541	4/8/2019 1603	3/26/2018 1454	4/21/2017 0753
DIABETIC SCREENING...				
Glucose, Non-Fasting				
HbA1C	5.7 * ▲			4.8 *

Imaging

- ▶ CT UPPER ABD AND PELVIS W 9/23/2019
- ▶ ADRENAL GLANDS: No significant abnormality noted., LYMPH NODES: No significant abnormality noted. PELVIS: Exam suboptimal due to beam hardening artifact from right hip prosthesis. UTERUS, ADNEXA: Status post hysterectomy. IMPRESSION: Unremarkable study.



Non tumorous (functional) hyperandrogenism

Polycystic ovary syndrome
Congenital adrenal
hyperplasia
Ovarian hyperthecosis
Obesity
States of insulin resistance
Endocrinopathies

Iatrogenic

Tumorous hyperandrogenism

Adrenal tumors

Ovarian tumors

Cushing's syndrome
Acromegaly

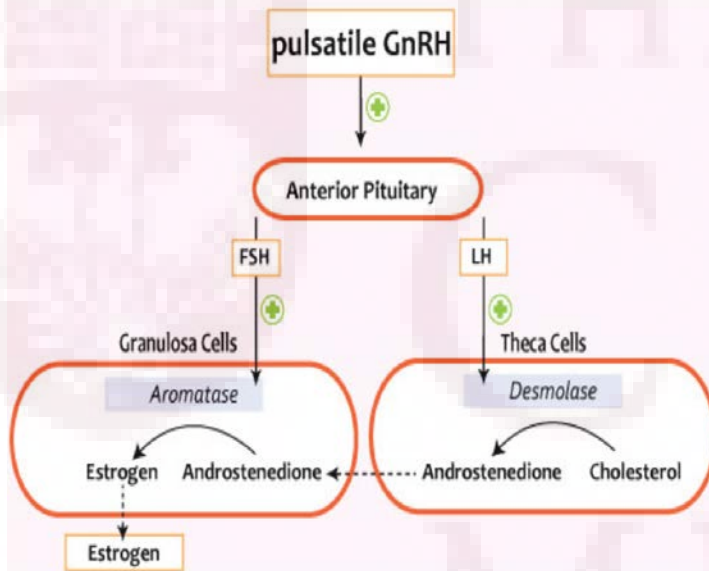
Testosterone/DHEA
supplementation
Antiepileptics (valproic acid
and oxcarbazepine)
Danazol

Androgen-secreting
carcinomas

Androgen-secreting adenomas
Sertoli–Leydig cell tumors
(androblastomas)

Hilus cell tumors
Granulosa theca cell tumors
Metastatic neuroendocrine/
gastrointestinal tumors
Cystadenomas

Is it physiologic/functional?

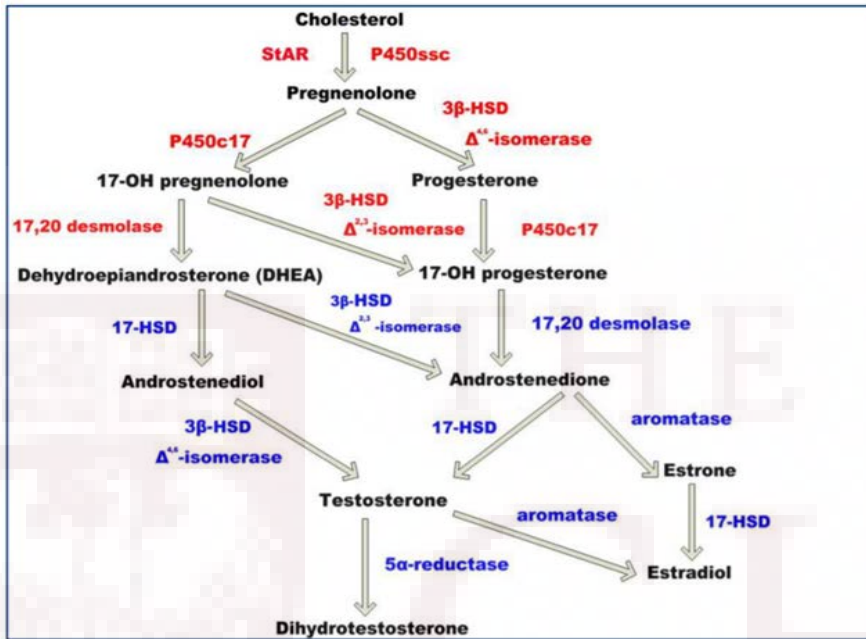


- ▶ The postmenopausal ovary remains hormonally active, secreting significant amounts of androgens and estrogens, many years after menopause [10]. Estrogen levels drop abruptly after menopause whereas androgen secretion gradually declines during the reproductive years. Subsequently, an imbalance among estrogens and androgens during menopause, amplified by a decrease in SHBG concentrations and may result in hyperandrogenic symptoms
- ▶ May be more pronounced in women with prior Dx of PCOS and CAH

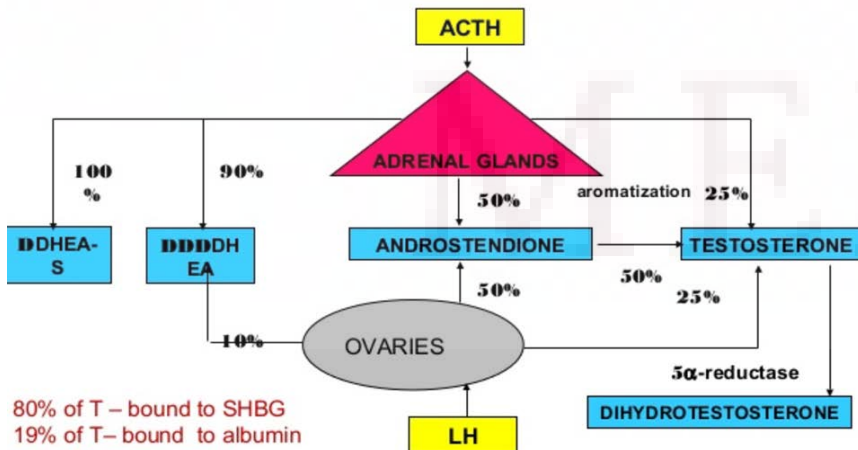
Is it exogenous?

- ▶ Exogenous testosterone
- ▶ supplements
- ▶ Medications

THE UNIVERSITY OF
CHICAGO
MEDICINE



Synthesis of androgens in women



80% of T – bound to SHBG
 19% of T – bound to albumin
 1% of T – is free, active


Is it adrenal?

Cushing's syndrome (CS) may also be diagnosed after menopause and cause symptoms or signs of androgen excess. Hirsutism can be found in approximately 50% of patients with CS mainly attributed to adrenal androgen excess; endogenous hypercortisolism also correlates positively with free androgen levels probably due to SHBG reduction. In contrast to CS secondary to adrenal carcinomas, signs of hyperandrogenism are usually mild in women with the adrenocorticotropin- (ACTH-) dependent CD and are virtually absent in women with adrenal adenomas

Androgen secreting adrenal tumors

- ▶ Incidence ~ 1-2cases/million population per year, usually malignant
- ▶ Adrenal androgen-secreting neoplasms are usually large and aggressive carcinomas that present also with Cushing's syndrome (25%) and have a very rapid progression and almost invariably a fatal outcome
- ▶ The differentiation between adrenal adenomas and carcinomas depends not on histology but on the benign or malignant clinical outcome after successful surgery.
- ▶ adrenal tumors frequently present with increase DHEAS levels, however testosterone was shown to be the most consistently elevated androgen
- ▶ probability of adrenal incidentaloma in patient over 70 yr of age reaches 7%

Adrenal Incidentaloma by Disease type



Is it ovarian?

Hyperthecosis ovary

- ▶ Hyperthecosis is a severe form of PCOS and results from an overproduction of androgens in the ovarian stromal cells. typically presents with slowly progressive acne and likely to be virilized.
- ▶ exact etiology is unclear thought to be related to elevated postmenopausal gonadotropin levels
- ▶ patients with hyperthecosis typically have normal serum dehydroepiandrosterone sulfate (DHEA sulfate) concentrations, testosterone >150 ng/dL and elevated gonadotropin levels
- ▶ Ultrasonography in women with hyperthecosis usually shows a bilateral increase in ovarian stroma and the ovaries appear more solid.
- ▶ characteristics of hyperthecosis include severe hyperandrogenism, insulin resistance (hyperinsulinism that further increase androgen production by binding to IGF1 receptors), hirsutism, and virilization
- ▶ Dx - histologic examination


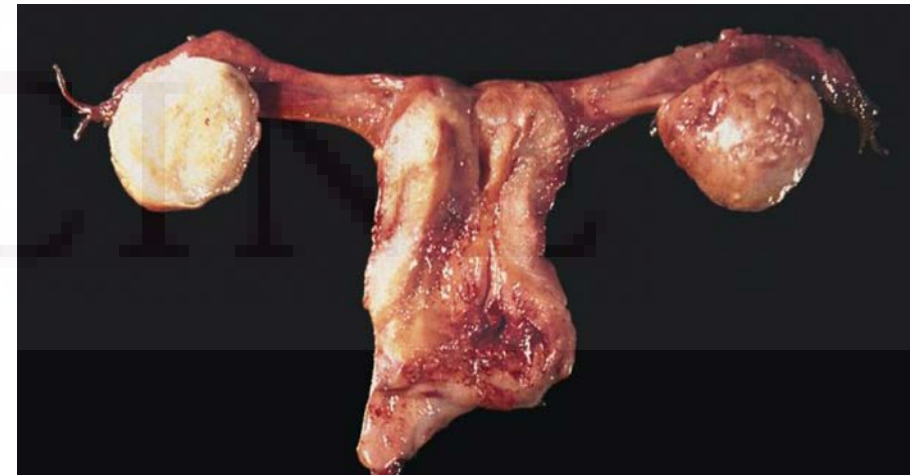


FIG. 2. Histological examination of the ovaries showing the nests of luteinized theca cells (*black arrows*) scattered throughout a hyperplastic ovarian stroma characteristic of ovarian hyperthecosis.



Is it ovarian?

- ▶ Sertoli-Leydig cell tumors (androblastoma) <1%, large at the time of presentation, ¼ presents at menopause
- ▶ granulosa-theca cell tumors (> estradiol, ~10% androgen secreting)
- ▶ hilus-cell tumors (more freq. in postmenopausal, small at the time of Dx, highly elevated testosterone levels);
- ▶ estradiol and testosterone, inhibin and anti-Müllerian hormone can be used as specific tumor markers
- ▶ majority of ovarian androgen-secreting tumors is of relatively large size, ranging between 3 and 12 cm at diagnosis, and only a small minority may elude detection with current imaging modalities.
- ▶ Besides sex cord-derived tumors, androgen secretion may be the result of ovarian metastases from neuroendocrine tumors, other malignancies, and serous cystadenomas that are not known to be steroidogenic. In such cases, ectopic secretion of b-hCG has been speculated to stimulate the steroidogenic cells through a paracrine mechanism

Histologic type	Age at presentation (years)	Incidence (of all ovarian neoplasms, %)	Hormone secretion	Symptoms	Bilaterality	Malignant potential
Sertoli-Leydig cell tumors (androblastomas)	Range, 2-75	0.5	Androgens, rarely estrogens	Virilization in about one-third of cases	Uncommon (1-2%)	Low
Granulosa cell tumors	40-70	2-3	Estrogens, rarely androgens	Postmenopausal bleeding, mass, rarely virilization	About 5%	Low
Sertoli cell tumors	Range, 7-79	0.1	Androgens, rarely estrogens	Virilization in about 30% of patients	Rare (1-2%)	Low
Hilus cell tumors	Peak at 6th decade	0.02	Androgens	Hirsutism and virilization in 50-75% of cases	Rare	Very rare

Gonadotroph cell tumor

Most hormonally silent tumors (NFPA), usually express gonadotropin subunits detectable by immunohistochemistry but not sufficient to elevate blood levels.

Most macro adenoma

Usually discovered because of space occupying defects, loss of vision, hypopit, hyperprolactinemia

Extremely rare

MANAGEMENT: surgery If threaten vision or macroadenoma. Although GnRH antagonists and somatostatin analogues modestly shrink tumor in some patients they are not sufficiently effective to be recommended as a therapy

Cell type	Hormone expression	% Nonfunctional tumors
Null cell	None	17
Oncocytoma	None	6
Silent corticotroph	ACTH	8
Silent somatotroph	GH	3
Gonadotrophs	Intact LH/FSH or subunits	40-79

Classification of nonfunctional pituitary adenomas by cell of origin



Acromegaly

THE
C
M

Acromegaly is a rare cause of hyperandrogenism in women, although hirsutism and less commonly acne can be found in up to 50% of the patients

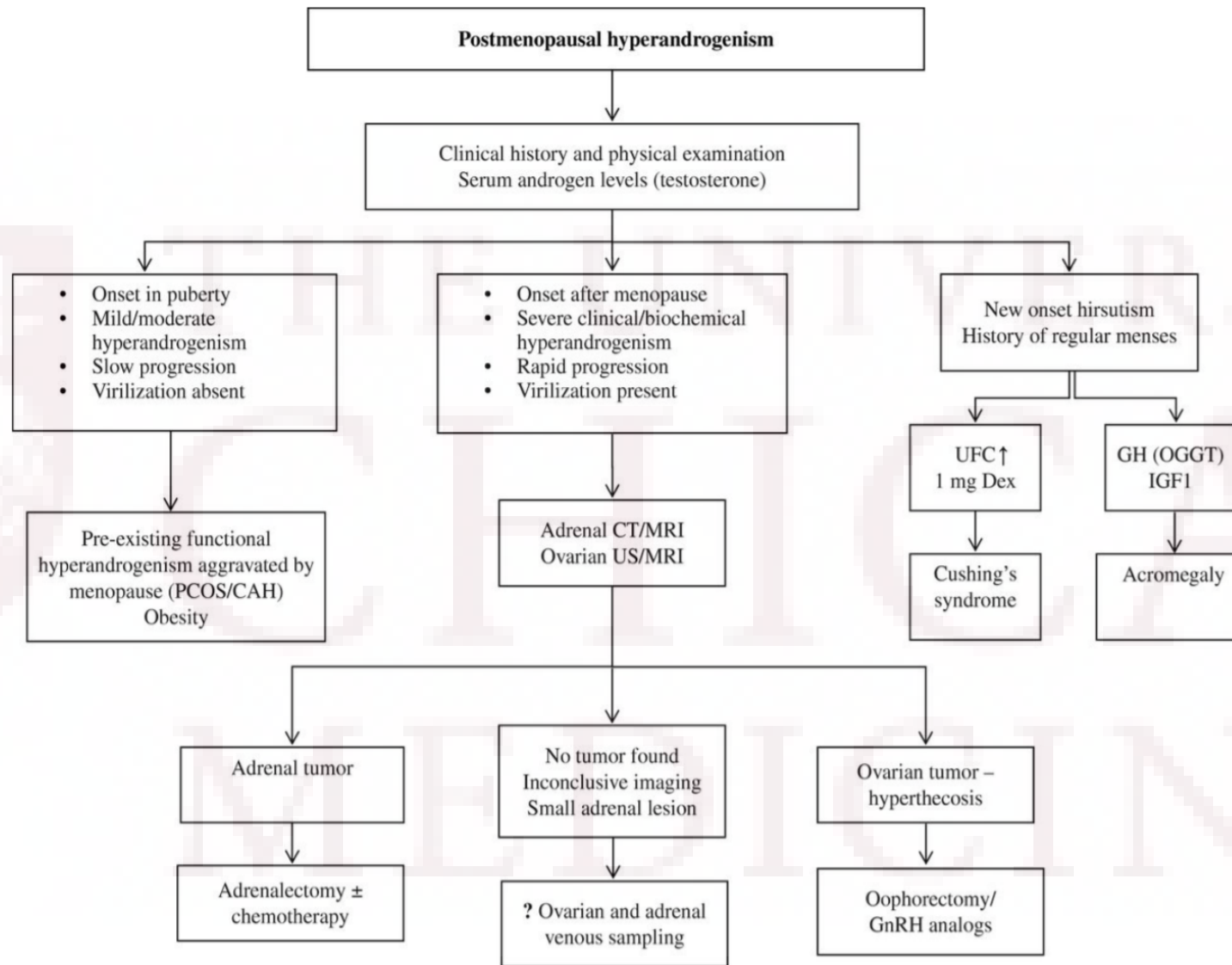
Growth hormone (GH) hypersecretion induces a state of ovarian hyperandrogenism that along with the increased insulin-like growth factor 1 levels and concomitant hyperinsulinemia stimulate ovarian testosterone production. In addition, GH levels correlate negatively with SHBG levels, contributing to elevated free androgen levels

Differential diagnosis of clinical hyperandrogenism

Diagnosis	Frequency (percent)	Age of onset years	Time of onset to presentation	Menstrual disturbance	Virilization
PCOS and related disorders	>95	15 to 25	Years	+/-	Rare
CAH	1 to 2	Congenital	Birth/adolescence/adulthood	+	+/-
Adrenal tumor	<1	Any time	Weeks-months	+	+
Ovarian tumor	<1	Any time	Weeks-months	+	+
Cushing's syndrome	<1	Any time	Months-years	+	+/-
Hyperthecosis ovary	<1	Pre- to post-menopause	Months-years	+	+

PCOS: polycystic ovary syndrome; CAH: congenital adrenal hyperplasia; (+): present; (-): absent; (+/-): present or absent.

From: Denny MC, Smith D, O'Shea D, McKenna TJ. Investigation of patients with atypical or severe hyperandrogenaemia including androgen-secreting ovarian teratoma. *Eur J Endocrinol* 2010; 162:213. Copyright © Society of the European Journal of Endocrinology 2010. Reproduced by permission.



Lab evaluation

- ▶ Pit. axis eval (LH, FSH, alpha-subunit, PRL, T4, T3, TSH, cortisol, IGF1, DHEA and DHEAS)
- ▶ cosyntropin stim (with venous sampling)
- ▶ Low dose dexamethasone suppression: sensitivity of 100% and a specificity of 88%
- ▶ GnRH suppression
- ▶ TRH stimulation (most NFTs are capable of synthesizing gonadotropin hormones and subunits (beta-FSH, beta-LH). Most patients in our study responded by either FSH, LH or alpha-SU secretion after TRH, independent of basal hormone levels. Furthermore, recent studies show that by measurement of TRH stimulated beta-FSH and beta-LH one might further improve the diagnostic tools. Gonadotropin response and possibly alpha-SU to TRH are also found in some patients with acromegaly. This could be a marker of a plurihormonal pituitary tumor)

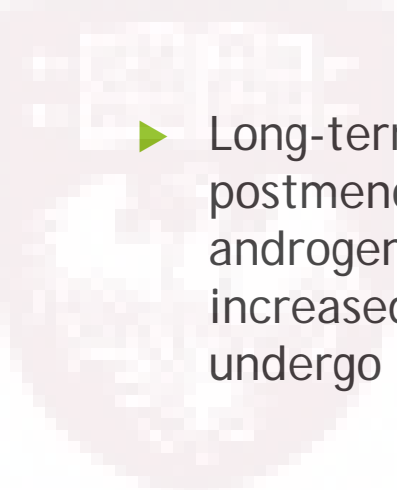
imaging

- ▶ CT/MRI adrenal
- ▶ US ovaries (transvaginal)
- ▶ If no tumor detected imaging of ovaries and adrenals after IV radiolabeled iodomethylnorcholesterol (NP-59) (detects active steroid producing tumors)
- ▶ **Selective ovarian or adrenal vein catheterization and sampling** may be considered before surgical exploration, but simultaneous catheterization of all adrenal and ovarian veins is difficult, with success rates as low as 26 - 45%. procedure consists of introducing a femoral catheter to reach both the adrenal and ovarian veins. Adrenal and ovarian venous sampling with peripheral vein control is performed simultaneously, androgen concentrations (usually testosterone) are measured, and the adrenal or ovarian/peripheral gradient is calculated. In the adrenal sample, cortisol is also measured to ensure that the catheter is properly placed. Unilateral adrenal and ovarian lesions are associated with an ipsilateral gradient and different threshold values have been proposed to discriminate tumoral from non-tumoral causes. Gradients >4.51 nmol/L have a reported sensitivity and specificity of 94% and 78%, respectively. Venous sampling has also been reported to predict the correct localization of the lesion in 66% of cases. The limitations of lesion localization using venous sampling include the technical difficulty associated with the accurate catheterization of 4 veins, with a 4 vein catheterization success rate of 27 to 45%.
- ▶ WBPET (9)

Treatment options

	Treatment
Non tumorous etiology	
Functional hyperandrogenism (PCOS, NCAH, and obesity)	Cyproterone acetate Spironolactone/flutamide Insulin sensitizers (metformin) Local therapies (hirsutism) Diet and exercise
Ovarian hyperthecosis iatrogenic	Surgical resection/GNRH analogs Discontinuation of drugs/ supplements
Endocrinopathies	
Cushing's syndrome	Surgical resection/adrenolytics
Acromegaly	Surgical resection/Somatostatin analog/pegvisomant
Tumorous etiology	
Adrenal tumors	Surgical resection (stage I/II) Adjuvant therapy – mitotane (stage III/IV)
Ovarian tumors	Oophorectomy GNRH analogs

PCOS, polycystic ovary syndrome; NCAH, non-classic adrenal hyperplasia.

- 
- Long-term GnRH agonist treatment is an acceptable choice for treatment of postmenopausal hyperandrogenism in patients where ovarian origin of androgen excess is ascertained, and especially in those patients who have an increased risk for surgery due to comorbidities or who are unwilling to undergo bilateral oophorectomy.

Back to our patient

Right Ovary

Visualized. Outline: smooth. Size 18 mm x 15 mm x 10 mm. Vol 1.5 cm³

Left Ovary

Visualized. Size 17 mm x 13 mm x 13 mm. Vol 1.5 cm³

Cyst(s) Size 12 mm x 10 mm x 13 mm. Mean 11.7 mm. Vol 0.817 cm³. unilocular cyst, smooth internal wall, cystic contents with 'ground glass' appearance, acoustic shadows not present, color score 2 (minimal color). Presumed endometrioma vs. unknown pathology

Cul de Sac

Visualized. No free fluid visualized

Impression

Ms. DUPREE is referred for an ultrasound at the Center for Advanced Care for high serum testosterone, hirsutism. History of hysterectomy in 1998. Patient states history of left ovarian cyst.

Multiple transabdominal and transvaginal images were taken to evaluate the pelvis.

Transvaginal ultrasound imaging is limited due to ovarian mass, therefore, transabdominal images were obtained to better visualize the entire pelvis.

Uterus is surgically absent.

Vaginal cuff appears unremarkable.

Right ovary appears within normal limits.

Left ovary is seen with a 12 x 10 x 13 mm unilocular cyst as described above.

No free fluid is visualized in the cul- de- sac.

Previous ultrasound on 12/10/2007.

Take home points

- ▶ Careful history taking is important
- ▶ Laboratory investigation can guide in a right direction, but none are 100% reliable
- ▶ Positive imaging findings must always be interpreted carefully while taking into account the clinical context of the patient
- ▶ After menopause, ovarian causes of hirsutism and virilization are more frequent compared with adrenal disorders and include androgen secreting neoplasms and benign disorders such as ovarian stromal hyperplasia and hyperthecosis

literature

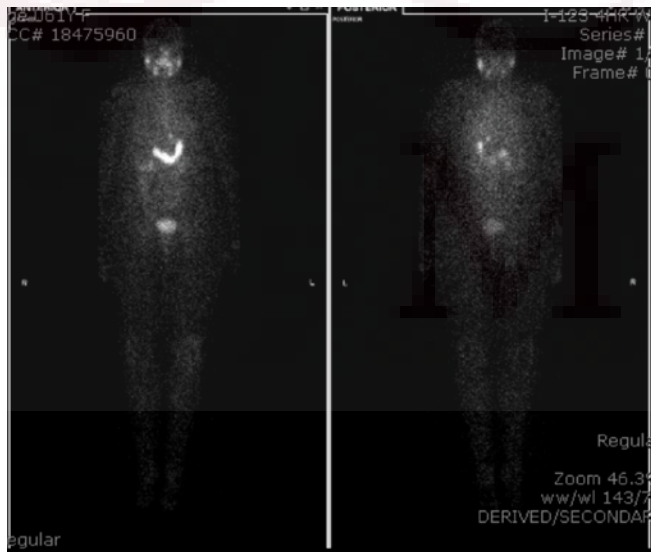
- ▶ 1 Case Rep Endocrinol. 2014; An Interesting Cause of Hyperandrogenemic Hirsutism, Murat Atmaca, 1, İsmet Seven, 2 Rıfki Üçler, 1 Murat Alay, 1 Veysi Barut, 2 Yaren Dirik, 2 and Yasin Sezgin 2
- ▶ 2 Clin Case Rep. 2017 High concentrations of LH cause virilization in a postmenopausal woman, Iram Ahmad and Bradley D. Anawalt
- ▶ 3 Thyroid. 1998 The effect of thyrotropin-releasing hormone on gonadotropin and free alpha-subunit secretion in patients with acromegaly and functionless pituitary tumors, Popovic V, Damjanovic S.
- ▶ 4 Williams Textbook of endocrinology 13th edition
- ▶ 5 J Clin Endocrinol Metab, August 2012, Management of Postmenopausal Virilization, Macarena Alpan¹, Jose¹ M. Gonza¹ lez-Casbas, Juan Sa¹ nchez, He¹ ctor Pia¹ n, and He¹ ctor F. Escobar-Morreale
- ▶ 6 J Women's Health Care 2018, Postmenopausal Hyperandrogenism, Rayhan A Lal and Marina Basina*
- ▶ 7 Hyperandrogenism in Postmenopausal Women, Solved After "White" Oophorectomy ,Guadalix, Sonsoles MD*; Vazquez, Tamara MD†; Jodar, Esteban MD, PhD*; Fernandez, Sofia MD., The Endocrinologist: November/December 2009
- ▶ 8 J Clin Endocrinol Metab. 2011 Gonadotropin-releasing hormone agonist treatment in postmenopausal women with hyperandrogenism of ovarian origin. Vollaard ES1, van Beek AP, Verburg FA, Roos A, Land JA.
- ▶ 9 Gynecol Oncol. 2001 Diagnosis and localization of testosterone-producing ovarian tumors: imaging or biochemical evaluation. Wang PH1, Chao HT, Liu RS, Cho YH, Ng HT, Yuan CC.
- ▶ 10. J Clin Endocrinol Metab. 2007 Ovarian androgen production in postmenopausal women. Fogle RH1, Stanczyk FZ, Zhang X, Paulson RJ.
- ▶ 11. Polycystic Ovary Syndrome: Evidence for Reduced Sensitivity of the Gonadotropin-Releasing Hormone Pulse Generator to Inhibition by Estradiol and Progesterone1 Carmen L. Pastor, Marie L. Griffin-Korf, Joseph A. Aloï, William S. Evans, John C. Marshall The Journal of Clinical Endocrinology & Metabolism, Volume 83, Issue 2, 1 February 1998
- ▶ 12, Mayo Clinic proceedings July 1996, Gonadotroph Adenoma of the Pituitary Gland: A Clinicopathologic Analysis of 100 Cases William F. Young Jr., M.D.a,b,**Correspondence information about the author M.D. William F. Young, Bernd W. Scheithauer, M.D.c, Kalman T. Kovacs, M.D., Ph.D.e, Eva Horvath, Ph.D.e, Dudley H. Davis, M.D.d, Raymond V. Randall, M.D.a,1
- ▶ 13 Neurosurgery. 2016 functional Gonadotroph Adenomas: Case Series and Report of Literature , David J. Cote, BS,1 Timothy R. Smith, MD, PhD, MPH,1 Courtney N. Sandler, MD, MPH,2 Tina Gupta, MD,2 Tejus A. Bale, MD,3 Wenya Linda Bi, MD, PhD,1 Ian F. Dunn, MD,1 Umberto De Girolami, MD,3 Whitney W. Woodmansee, MD,2 Ursula B. Kaiser, MD,2 and Edward R. Laws, Jr, MD1
- ▶ 14. European journal of endocrinology 2015, Hyperandrogenism after menopause. Marios C Markopoulos, Evanthia Kassi, Krystallenia I Alexandraki, George Mastorakos1 and Gregory Kaltsas
- ▶ 15 Novel Molecular Signaling and Classification of Human Clinically Nonfunctional Pituitary Adenomas Identified by Gene Expression Profiling and Proteomic Analyses, Cancer Research 65(22):10214-22 · December 2005

	6/5/2017 1701	10/9/2017 1343	4/10/2018 1217	4/18/2018 0839	5/11/2018 1423	7/18/2018 1127
THYROID FUNCTION						
ALPHA-SUBUNIT						
Thyroxine, Free	1.24 *	1.38 *	2.20 * ▲	0.63 * ▼	1.05 *	1.37 *
Reverse Triiodothy...					201 *	
Thyroglobulin Ab			<0.4			
Thyroglobulin (Thy...			<1 *			
THYROID STIMULATIN...						
Thyroid Perox. Ab			0.6 ▲	0.5 * c ▲		
Thyrotropin	0.66	0.19 ▼	0.01 ▼		1.28	0.73
Triiodothyronine			246 ▲	79 ▼	96	

► US thyroid 4/16/2019

Small relatively echogenic appearing soft tissue foci in the thyroid bed bilaterally, suspected to be residual thyroid tissue. Correlation with nuclear medicine study and surgical history recommended

NM THYROID IMG SNG/MLT UPTKS QNT MSRMNTS, 4/17/2018 : no functioning thyroid tissue



Postmenopausal hyperandrogenism

► a state of relative or absolute androgen excess originating from either the adrenals and/or the ovaries, clinically manifested as the appearance and/or increase in terminal hair growth or the development of symptoms/signs of virilization

