



THE UNIVERSITY OF
CHICAGO
MEDICINE &
BIOLOGICAL
SCIENCES

“51 Year Old Female with
Palpitations”



THE UNIVERSITY OF
CHICAGO
MEDICINE

ENDORAMA:
51 Year Old Female with Palpitations

Monika Darji

September 12th, 2019

Objectives

- Discuss the workup and diagnosis of pheochromocytoma
- Discuss the role of genetic testing in pheochromocytoma
- Review the criteria for diagnosis of malignant pheochromocytoma

Chief Complaint

51 year old female presents with palpitations

HPI

- Presents with palpitations for 1 year
 - Progressively getting worse over last several months
 - Lasts minutes to hours, occurs multiple times per day
 - Associated with nausea, anxiety, headaches, diaphoresis
 - Noticed it was associated with blood pressure spikes
 - No previous history of palpitations
 - No known cardiac history

Review of Systems

- Constitutional: **+fatigue, diaphoresis**; No fever, chills, activity change
 - HEENT: **+headaches**; No visual disturbance, hearing loss, congestion, sore throat, neck pain
 - Resp: **+dyspnea on exertion**; No cough
 - CV: **+palpitations**; No CP, LE edema
 - GI: **+nausea**; No nausea or vomiting. No abdominal pain, d/c, or blood in stool
 - MSK: **+myalgias**
 - Skin: No rashes or ulcers.
 - Neuro: No lightheadedness, seizures, syncope
 - Endo: No heat/cold intolerance. No hair/skin changes noted
 - Heme: No adenopathy
 - Psych: **+anxiety, depression**
-

Additional history

- Past Medical History: polymyositis, hypertension, asthma, depression
- Past Surgical History: none
- Family History: mother has asthma, father had lung cancer
- Social History: smokes half a pack of cigarettes per day for the last 20 years, social drinker, denies illicit drug use

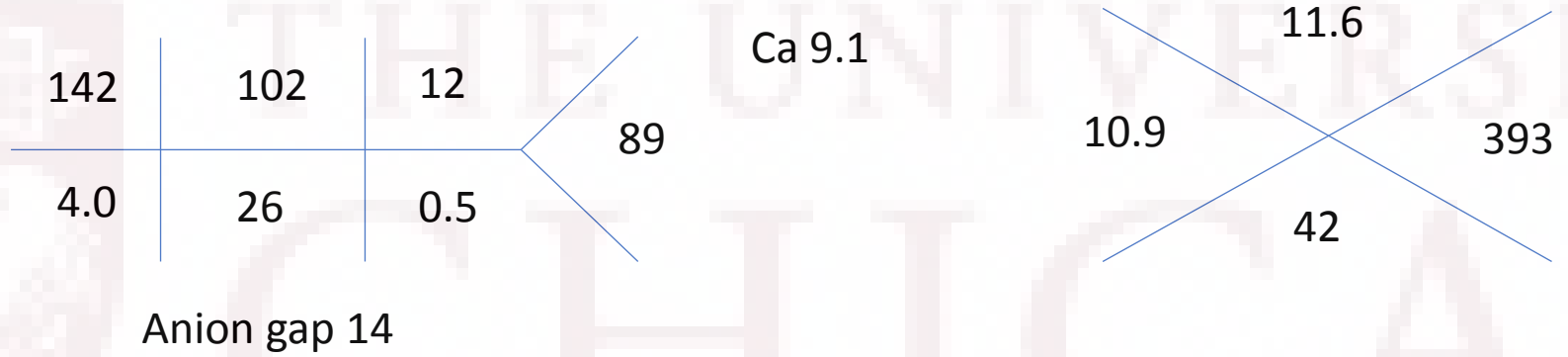
Additional history

- Meds: prednisone 15mg, azathioprine 200mg, amlodipine 5mg, fluoxetine 20mg, albuterol
- Allergies: NKDA

Physical Exam

- Vitals: 139 kg, BMI 42, Temp 97.5, **HR 105**, RR 18, BP 108/78, SpO2 99%
 - General: **Obese**; No apparent distress. Appears stated age.
 - HEENT: Normocephalic. PERRL, EOMI. No pharyngeal erythema.
 - Neck: No neck tenderness. No thyromegaly or thyroid nodules appreciated.
 - Cardiovascular: **Tachycardic**. Regular rhythm. **Trace peripheral edema**.
 - Pulmonary/Chest: Clear to auscultation bilaterally.
 - Gastrointestinal: Soft, non-tender, non-distended. No rebound or guarding.
 - Musculoskeletal: Normal bulk and tone, no major deformities.
 - Neurological: Alert & oriented, CN 2-12 intact.
 - Skin: No rashes or bruises.
 - Psychiatric: **Anxious**. Normal thought content, appropriate.
-

Labs



| | | | | | |
|-----------------|-----|----------------------|----|-----|------|
| Total protein | 8.1 | Alkaline phosphatase | 86 | TSH | 1.74 |
| Albumin | 4.5 | ALT | 26 | | |
| Total bilirubin | 0.8 | AST | 12 | | |

Differential diagnosis

- Pheochromocytoma
 - Hyperthyroidism
 - Carcinoid
 - Insulinoma
 - Paroxysmal supraventricular tachycardia
 - Ischemic heart disease
 - Anxiety disorder
 - Substance use or withdrawal
-

Workup

| Lab | Value | Reference range |
|---------------------------|----------------|---|
| Plasma normetanephrine | 4.4 nmol/L | < 0.90 nmol/L |
| Plasma metanephrine | < 0.20 nmol/L | < 0.50 nmol/L |
| Urine norepinephrine | 1,111 mcg/24hr | 15 – 80 mcg/24hr |
| Urine epinephrine | 16 mcg/24hr | < 21 mcg/24hr |
| Urine dopamine | 239 mcg/24hr | 65 – 400 mcg/24hr |
| Urine total metanephrines | 3,797 mcg/24hr | 164 – 588 (normotensive) < 1300 (hypertensive) |
| Urine normetanephrines | 3,614 mcg/24hr | 128 – 484 (normotensive) < 900 (hypertensive) |
| Urine metanephrines | 183 mcg/24hr | 30 – 180 (normotensive) < 400 (hypertensive) |

Cardiac workup

- Event monitor
 - Sinus rhythm with episodes of sinus tachycardia and junctional rhythm during which the patient was symptomatic
- 2D echocardiogram
 - LV EF 44%
 - Mild left ventricular hypertrophy
- MRI cardiac stress
 - No perfusion defects or ischemia
 - No prior myocardial infarction
 - Concern for early myocarditis or diffuse interstitial fibrosis
- Cardiac PET
 - FDG uptake in the inferior wall, inferolateral wall, and apex of the LV, c/w inflammatory change in the myocardium

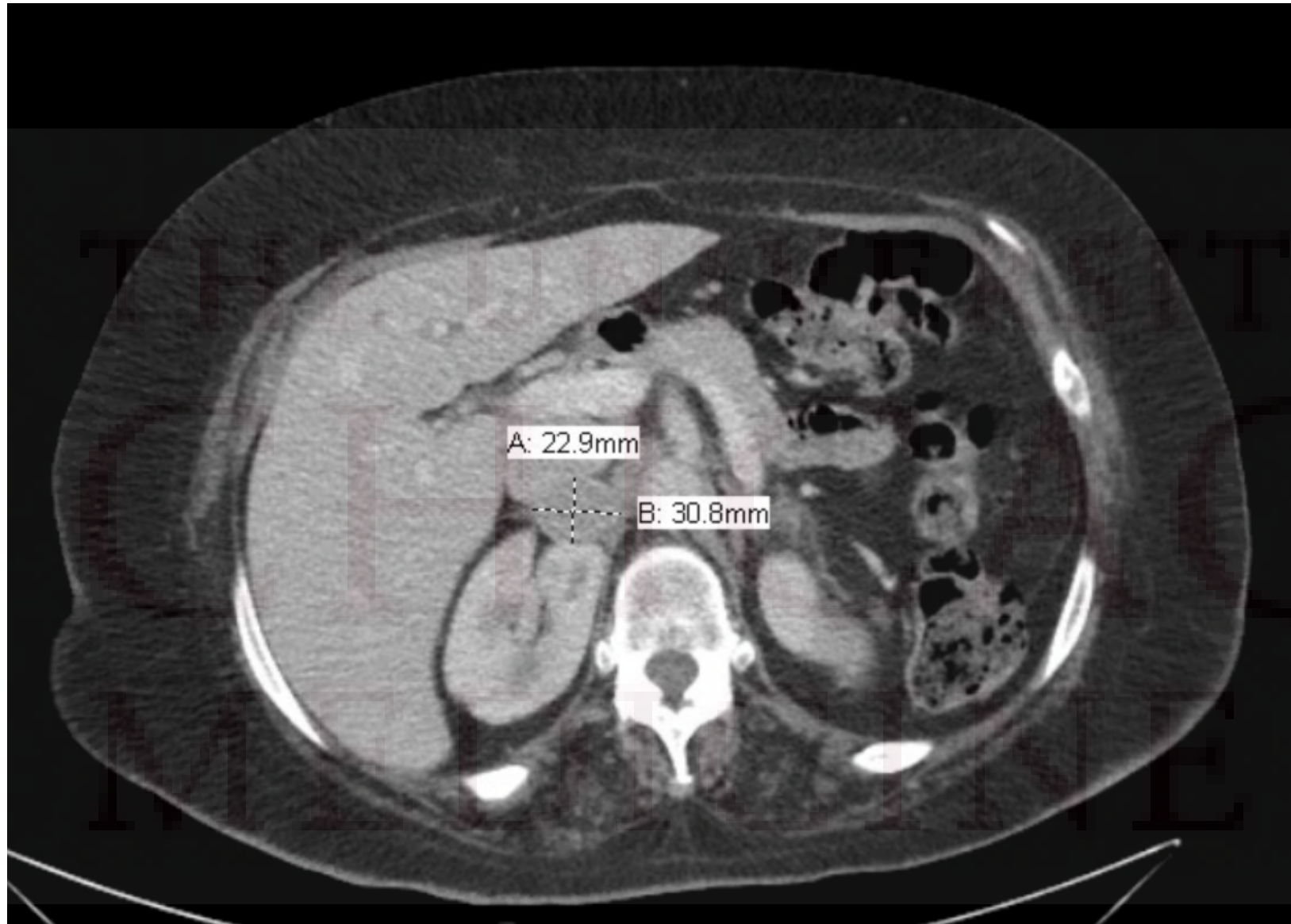
Cardiology appointment

- Heart failure thought to be 2/2 inflammatory myopathy, unlikely ischemic given normal stress perfusion
- Beta blocker held
- Started on lasix 20mg daily, doxazosin 1mg QHS
- ACE-I held given borderline BPs
- RHC with biopsy



Imaging

- CT abdomen/pelvis
 - Enhancing right adrenal nodular lesion measuring 3.1 x 2.3 cm
 - Absolute washout of 73%, relative washout 40%
 - High absolute attenuation within portal venous phase
 - Left adrenal is normal in appearance





Pheochromocytoma and Paragangliomas (PPGL)

- Pheochromocytoma – tumor arising from adrenal medullary chromaffin cells that commonly produce one of more catecholamines (80 - 85% chromaffin cell tumors)
- Paraganglioma – tumor arising from extra-adrenal chromaffin cells of the sympathetic paravertebral ganglia of thorax, abdomen, and pelvis (15- 20 % chromaffin cell tumors)
 - Can also arise from parasympathetic ganglia along glossopharyngeal and vagal nerves in neck and at base of skull

PPGL

- Prevalence in patients with hypertension estimated to be 0.2-0.6%
- In patients with incidentally discovered adrenal masses on imaging, estimated 5% have pheochromocytomas
- At least 1/3 of patients with PPGLs have disease causing germline mutations
- Most common in the fourth to fifth decade of life
- Equally common in men and women



Clinical Presentation

- Symptoms present in approximately 50% of patients
- Classic triad – episodic headache, diaphoresis, and tachycardia
- Hypertension can be sustained or paroxysmal – most common sign
- Other symptoms include palpitations, tremor, generalized weakness, dyspnea
- Less common symptoms/signs - orthostatic hypotension, cardiomyopathy

Table I. Most Common Symptoms and Signs in Patients (Almost All Adults) With Pheochromocytoma Associated With Paroxysmal or Persistent Hypertension

| SYMPTOMS | PAROXYSMAL N=37 % | PERSISTENT N=39 % |
|--|-------------------------|-------------------------|
| Headaches (severe) | 92 | 72 |
| Excessive sweating (generalized) | 65 | 69 |
| Palpitations with or without tachycardia | 73 | 51 |
| Anxiety, nervousness, fear of impending death, or panic | 60 | 28 |
| Tremulousness | 51 | 26 |
| Pain in chest, abdomen (usually epigastric), lumbar regions, lower abdomen, or groin | 48 | 28 |
| Nausea with or without vomiting | 43 | 26 |
| Weakness, fatigue, prostration | 38 | 15 |
| Weight loss (severe) | 14 | 15 |
| Dyspnea | 11 | 18 |
| Warmth or heat intolerance | 13 | 15 |

Noteworthy are painless hematuria, urinary frequency, nocturia, and tenesmus in pheochromocytoma of the urinary bladder.



Indications for testing

- Patients presenting with the classic triad of symptoms or hyperadrenergic episodes
- Early onset of hypertension or resistant hypertension
- Familial syndrome like MEN2, VHL, NF1
- Family history of pheochromocytoma
- Incidental adrenal mass with or without hypertension
- Idiopathic dilated cardiomyopathy

Interfering medications

Medications that may increase measured levels of catecholamines and metanephrines

| |
|---|
| Tricyclic antidepressants |
| Levodopa |
| Drugs containing adrenergic receptor agonists (eg, decongestants) |
| Amphetamines |
| Bupropion and most psychoactive agents |
| Prochlorperazine |
| Reserpine |
| Withdrawal from clonidine and other drugs |
| Ethanol |

Initial Testing

- 24-hour urinary fractionated metanephrines or plasma fractionated metanephrines (drawn supine with an indwelling cannula for 30 minutes)
- Plasma fractionated metanephrines
 - Sensitivity of 96 to 100 percent, specificity of 85 to 89 percent
 - Can consider as a first-line test for pheochromocytoma for patients with high suspicion of pheochromocytoma
 - Family history of pheochromocytoma
 - Hereditary syndrome
 - Past history of resected pheochromocytoma

Table 3. Sensitivities and Specificities of Biochemical Tests for Diagnosis of Hereditary and Sporadic Pheochromocytoma*

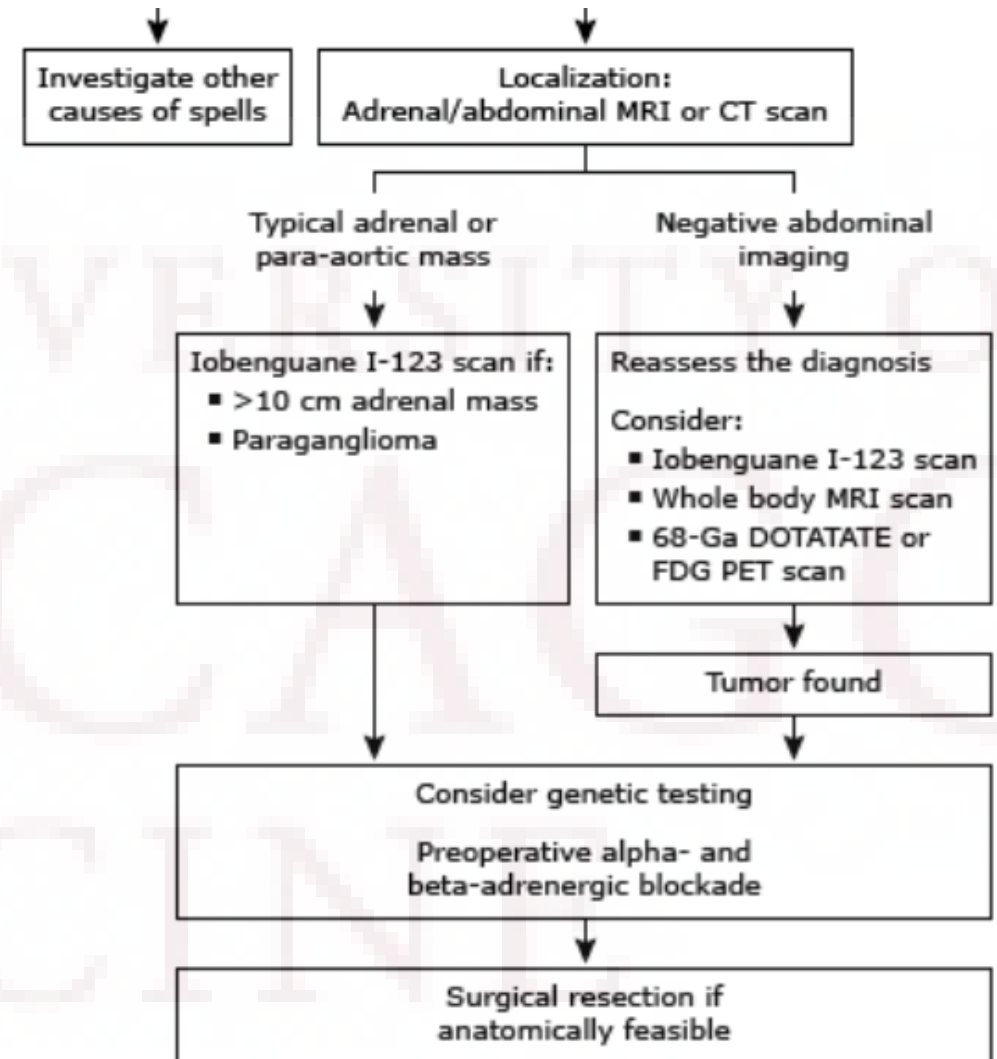
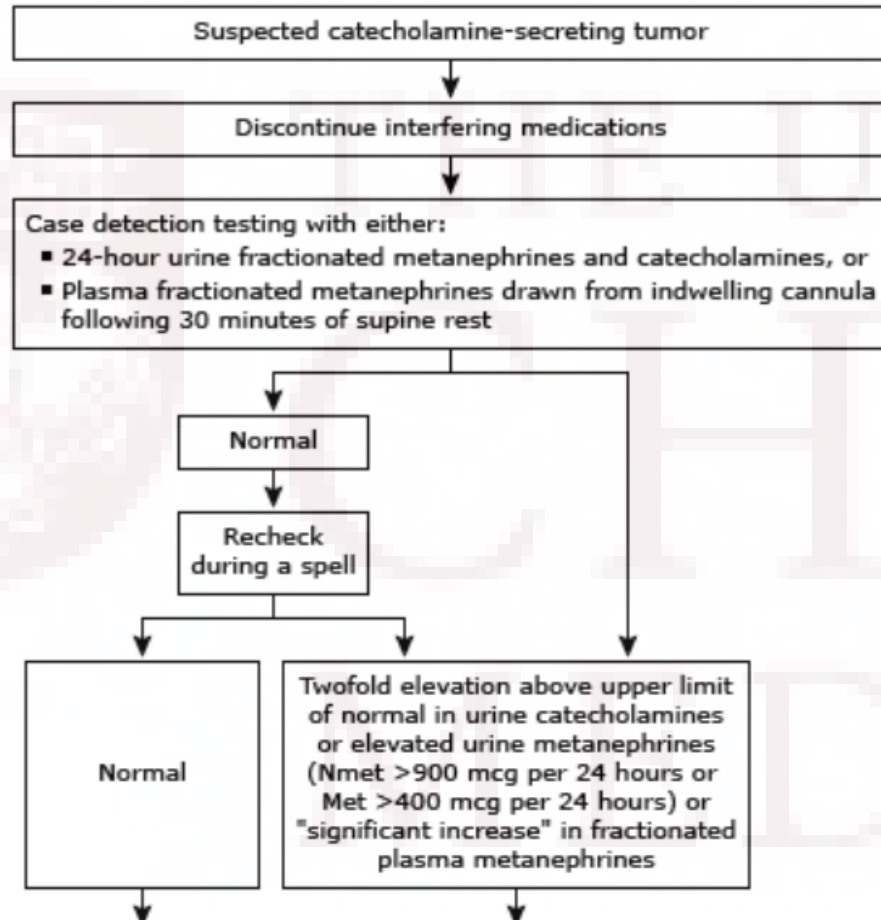
| | Sensitivity, %† | | Specificity, %‡ | |
|----------------------------|-----------------|--------------|-----------------|--------------|
| | Hereditary | Sporadic | Hereditary | Sporadic |
| Plasma | | | | |
| Free metanephrines | 97 (74/76) | 99 (137/138) | 96 (326/339) | 82 (249/305) |
| Catecholamines | 69 (52/75) | 92 (126/137) | 89 (303/339) | 72 (220/304) |
| Urine | | | | |
| Fractionated metanephrines | 96 (26/27) | 97 (76/78) | 82 (237/288) | 45 (73/164) |
| Catecholamines | 79 (54/68) | 91 (97/107) | 96 (312/324) | 75 (159/211) |
| Total metanephrines | 60 (27/45) | 88 (61/69) | 97 (91/94) | 89 (79/89) |
| Vanillylmandelic acid | 46 (30/65) | 77 (66/86) | 99 (310/312) | 86 (132/153) |

*The reference limits used to calculate sensitivity and specificity are presented in Table 2.

†For free plasma metanephrines or urinary fractionated metanephrines, sensitivity was calculated from patients with pheochromocytoma and false-negative test results for both normetanephrine and metanephrine. For plasma and urine catecholamines, sensitivity was calculated from patients with both false-negative test results for nonrepinephrine and epinephrine. Numbers in parentheses indicate true positive over true positive plus false-negative.

‡For free plasma metanephrines or urinary fractionated metanephrines, specificity was calculated from patients without pheochromocytoma and with false-positive test results for either normetanephrine or metanephrine. For plasma and urine catecholamines, specificity was calculated from patients without pheochromocytoma and with false-positive test results for either nonrepinephrine or epinephrine. Numbers in parentheses indicate true negative over true negative plus false-positive.

Evaluation and treatment of catecholamine-producing tumors



Imaging

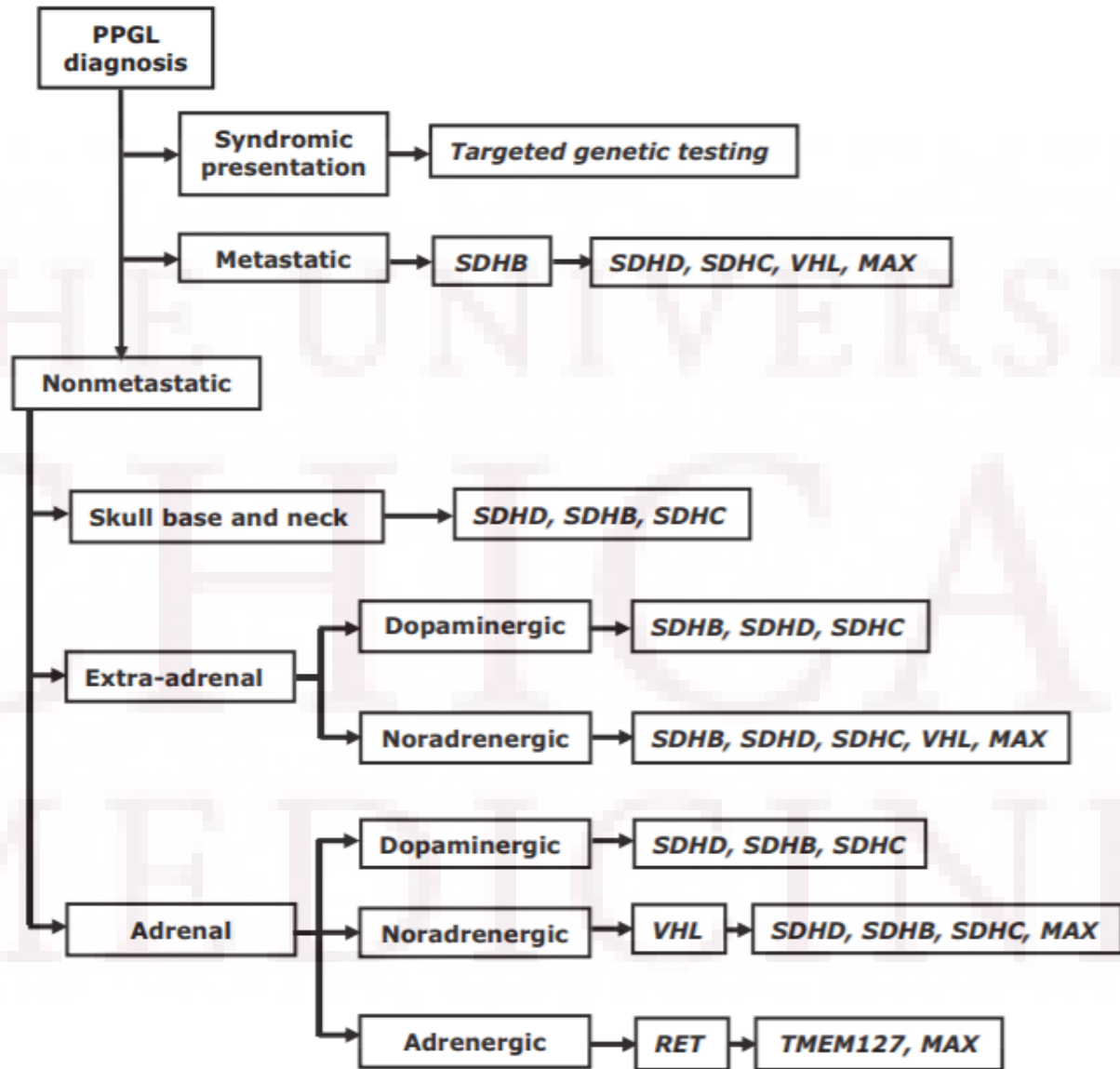
- CT abdomen/pelvis
 - First choice imaging modality
 - Increased attenuation on nonenhanced CT (>20 Hounsfield units)
 - Increased mass vascularity
 - Delay in contrast medium washout
- MRI abdomen/pelvis
 - High signal intensity on T2-weighted MRI
- Iobenguane I-123
 - >10 cm adrenal pheochromocytomas
 - Paragangliomas
- FDG-PET
 - More sensitive than I-123 or CT/MRI for detection of metastatic disease

Genetic testing

- At least one-third of all patients with PPGLs have disease-causing germline mutations
 - More likely to be bilateral adrenal pheochromocytomas or paragangliomas
- Familial disorders associated with pheochromocytoma:
 - Von Hippel-Lindau syndrome (VHL) – 10-20%
 - Multiple endocrine neoplasia type 2 (MEN2) – 30-50%
 - Neurofibromatosis type 1 (NF1) – 0.1 to 5.7%
- Most cases of familial paraganglioma are caused by mutations in the succinate dehydrogenase (SDH) subunit genes

Genetic Testing

- Guidelines recommend shared decision making for genetic testing
- Consider genetic testing for patients with:
 - Paraganglioma
 - Bilateral adrenal pheochromocytoma
 - Unilateral adrenal pheochromocytoma with family history of pheochromocytoma or diagnosed at young age (<35yo)
 - Clinical features suggestive of hereditary syndrome



Back to our patient

- Seen by endocrine surgery in clinic and referred to anesthesiology for pre-operative evaluation and optimization of alpha blockade
- Symptoms improved since stopping beta-blocker and starting doxazosin – reported decrease in the number and length of “attacks”
- Underwent laparoscopic right adrenalectomy
- Postoperative course was complicated by hypotension requiring a brief ICU stay and vasopressors
- Discharged to subacute rehab

Pre-op management

Table 9. Presurgical Medical Preparation

| Drug | Starting Time | Starting Dose | Final Dose ^b |
|--|--|-------------------------|-------------------------|
| Preparation 1 Phenoxybenzamine or Doxazosine | 10–14 d before surgery 10–14 d before surgery | 10 mg b.i.d. 2 mg/d | 1 mg/kg/d 32 mg/d |
| Preparation 2 Nifedipine ^a or Amlodipine ^a | As add-on to preparation 1 when needed As add-on to preparation 1 when needed | 30 mg/d 5 mg/d | 60 mg/d 10 mg/d |
| Preparation 3 Propranolol or Atenolol | After at least 3–4 d of preparation 1 After at least 3–4 d of preparation 1 | 20 mg t.i.d. 25 mg/d | 40 mg t.i.d. 50 mg/d |

Abbreviations: b.i.d., twice daily; t.i.d., three times daily.

^a Add when blood pressure cannot be controlled by α -adrenoceptor blockade (preparation 1).

^b Higher doses usually unnecessary.

Post op visit

- 1 month post op visit – patient was feeling well, symptoms resolved

| Lab | Value | Reference range |
|------------------------|---------------|-------------------------|
| Plasma dopamine | < 25 pg/mL | < 30 pg/mL |
| Plasma norepinephrine | 383 pg/mL | 70 – 750 pg/mL (supine) |
| Plasma epinephrine | < 25 pg/mL | < 111 pg/mL (supine) |
| Plasma normetanephrine | 0.52 nmol/L | < 0.90 nmol/L |
| Plasma metanephrine | < 0.20 nmol/L | < 0.50 nmol/L |

Pathology

- Right adrenal gland – 3 cm pheochromocytoma
 - “Immunohistochemical stain performed show that the neoplastic cells are diffusely positive for synaptophysin and chromogranin, and the sustentacular cells are highlighted by S100”
 - No adverse histologic features identified such as capsular or vascular invasion, extension into peri-adrenal adipose tissue, large nests or diffuse growth, necrosis, high cellularity, cell spindling, cellular monotony, increased or atypical mitosis, profound nuclear pleomorphism, and nuclear hyperchromasia
 - PASS score of 0
 - Overall, the histological features suggest a benign behavior



Malignant Pheochromocytoma

- Defined as presence of metastases in nonchromaffin tissues
 - Local invasion to surrounding tissues and organs or distant metastases
- Prevalence varies between 10-17%
- Histologically and biochemically similar to benign pheochromocytomas
- May occur as long as 53 years after resection

Table 1 PASS (Pheochromocytoma of Adrenal gland Scaled Score) by Thompson [9]

| Microscopic feature | Score |
|--|-------|
| Capsular invasion | 1 |
| Vascular invasion | 1 |
| Extension into the peri-adrenal adipose tissue | 2 |
| Presence of large nests or diffuse growth (in >10% of tumour volume) | 2 |
| Central tumour necrosis (in the middle of large nests) or confluent necrosis | 2 |
| High cellularity | 2 |
| Tumour cell spindling even when focal | 2 |
| Cellular monotony | 2 |
| Increased mitotic figures (>3/10 HPF) | 2 |
| Atypical mitotic figures | 2 |
| Profound nuclear polymorphism | 1 |
| Nuclear hyperchromasia | 1 |

HPF high-power field

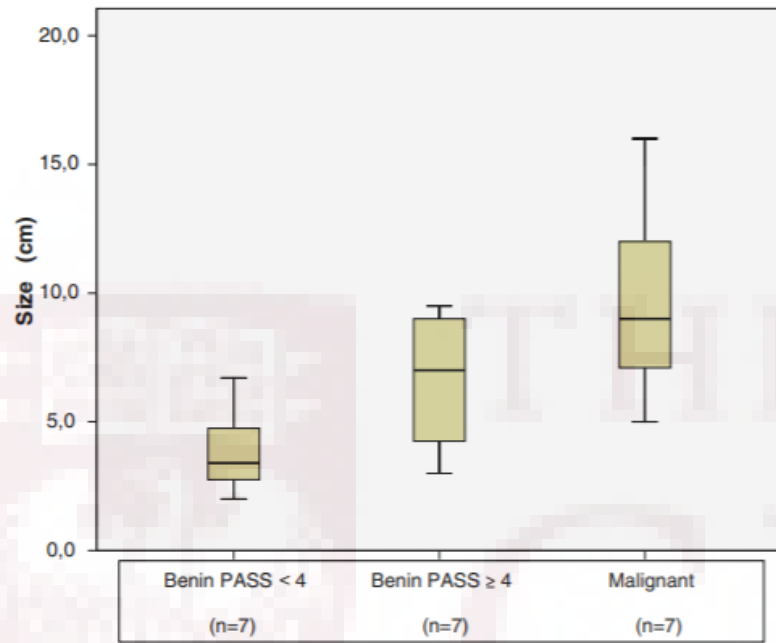


Fig. 1 Tumour size distribution between three groups

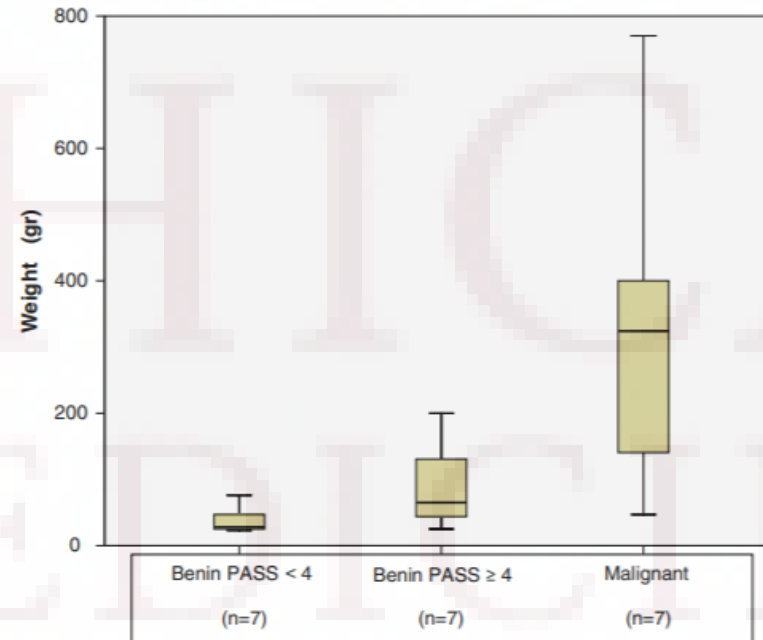


Fig. 2 Tumour weight distribution between three groups

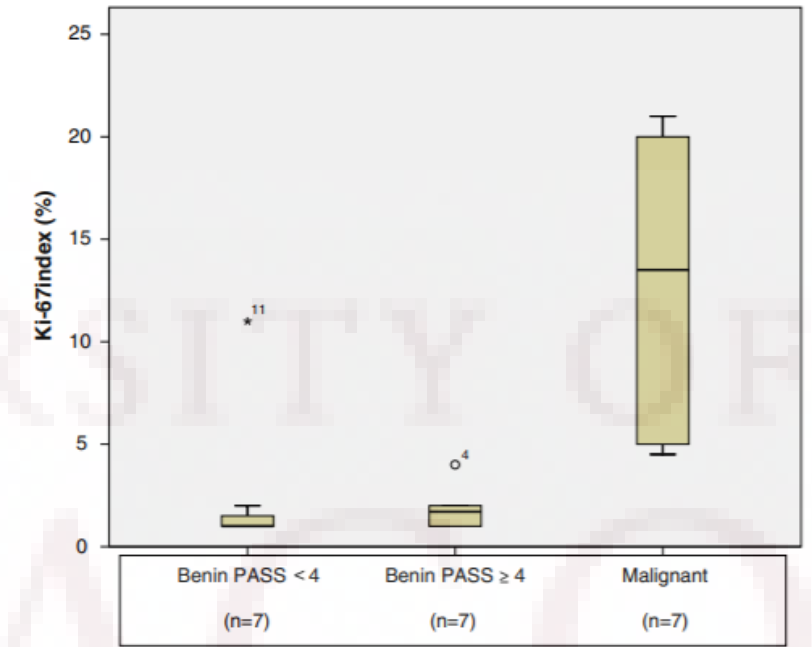


Fig. 3 Immunohistochemical expression of Ki-67 between three groups



Malignant Pheochromocytoma

- The size and weight of the pheochromocytoma are directly related to PASS score and malignancy
- High risk of malignancy or recurrence
 - Presence of tumor necrosis
 - High mitotic rate greater than 3 to 10 HPF
 - Ki-67 index >4%
 - pS100 absence

Follow up

- Endocrinology follow up tomorrow!
- Medical genetics referral
- Annual biochemical testing to assess for recurrent or metastatic disease

References

1. Young, W. Clinical presentation and diagnosis of pheochromocytoma. Uptodate (2019)
2. Young, W. & Kebebew, E. Treatment of pheochromocytoma in adults (2019).
3. Lenders et al. Pheochromocytoma and Paraganglioma: An Endocrine Society Clinical Practice Guideline. *J Clin Endocrinol Metabolism* (2014); 99(6):1915–1942.
4. Phillips, R. A. Pheochromocytoma. *The Journal of Clinical Hypertension* (2002); 62-72.
5. Lenders et al. Biochemical Diagnosis of Pheochromocytoma: Which Test is Best? *JAMA* 2002.
6. De Wailly, P. et al. Malignant pheochromocytoma: new malignancy criteria. *Langenbecks Arch Surg* (2012) 397:239–246.
7. Thompson, L. Pheochromocytoma of the Adrenal Gland Scaled Score (PASS) to Separate Benign From Malignant Neoplasms: A Clinicopathologic and Immunophenotypic Study of 100 Cases. *The American Journal of Surgical Pathology* (2002) 26:551-566.
8. Parenti et al. Updated and New Perspectives on Diagnosis, Prognosis, and Therapy of Malignant Pheochromocytoma/Paraganglioma. *Journal of Oncology* (2012)