



THE UNIVERSITY OF
CHICAGO
MEDICINE &
BIOLOGICAL
SCIENCES

“A 56 year old woman presenting
with bilateral adrenal lesions ”

Dr. Dickens does not have any
relevant financial relationships with
any commercial interests.



THE UNIVERSITY OF
GEOFFREY HAGG
MEDICINE

ENDORAMA: A 56 year old woman presenting with bilateral adrenal lesions

Laura Dickens

May 10, 2018

Objectives

1. Review the differential diagnosis of bilateral adrenal lesions.
2. Review the imaging characteristics of different etiologies of adrenal masses.
3. Understand the challenge of making a biochemical diagnosis of pheochromocytoma in acute illness.
4. Discuss characteristics of metastatic disease of the adrenal glands.

Chief Complaint

56 year old woman with a history of bilateral pleural effusions s/p R pleural drain presenting with subacute leg swelling, shortness of breath, weakness, and loss of appetite.

HPI

- Patient has a known history of bilateral pleural effusions which have been present for several years and despite repeat sampling of the fluid, etiology has not been determined
- One year ago she had a right pleural drainage catheter placed
- Typically drains 800cc q3-4 days
- At the time of admission, she reported three weeks of leg swelling and increased frequency of drainage of her pleural catheter (q2-3 days)
- Denies worsening DOE, orthopnea, or chest pain, cough, wheezing, or URI symptoms. No fevers or night sweats.
- She has reduced appetite and has lost 40lbs in the past year. She endorses constipation, no diarrhea, abdominal pain, nausea or vomiting.

PMH:

Bilateral pleural effusions

PSH:

None

ROS:

+leg swelling

+increased pleurX drainage

+decreased appetite

+weight loss

+constipation

Meds: None

Allergies: None known

Social:

Lives with sister, worked in accounting. Denies tobacco/ETOH/drugs.

Family:

Colorectal cancer (father, age 70)

Sarcoidosis (brother, 2 maternal cousins)

Physical exam

VITALS: Temp 36.9, BP **93/62**, HR **106**, RR 15, O2 sat 97% on RA, 5'4", 130lbs, BMI 22

General: pleasant & non-distressed, resting comfortable

HENT: **Bilateral proptosis, no scleral injection, normal EOM**

Neck: no swelling, redness, no adenopathy

Pulm: **Breath sounds reduced at bases bilaterally (L>R), good air movement, no wheezes or rhonchi, trace crackles present**

CV: regular rate & rhythm, no murmur, no gallop or rubs. No JVD, no HJ Reflex

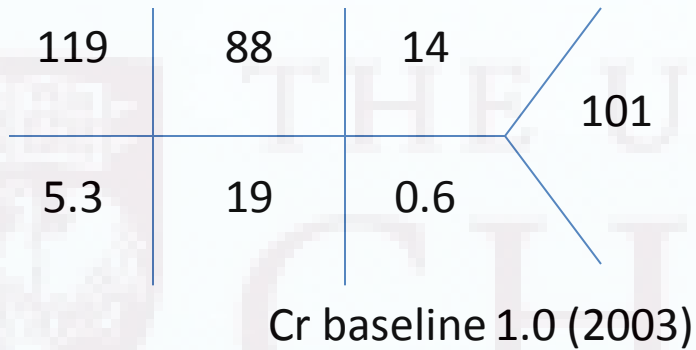
Abd: abdomen mildly distended but soft, BS normoactive, no TTP

Ext: **3+ pitting edema to thigh bilaterally, warm and well perfused**


Skin: no rashes, bruising, erythema.

Neuro: AAO x 3, appropriate, moving all extremities, CN II-XII grossly intact

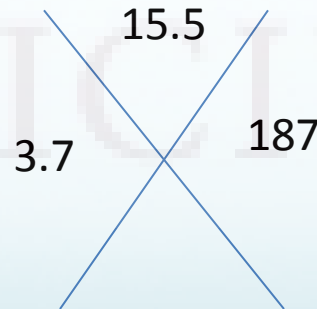
Admission Labs



Ca 7.6
Mg 2.0
Ph 2.4



Lactate 3.8
BNP 2434
Troponin 0.03
Serum osmolality 259
Urine osmolality 184
Urine Na <20
GGT 133



Neutrophils 85%

Pleural fluid studies

- According to the traditional **Light's Criteria** Rule, if at least one of the following three criteria (ie, component tests of the rule) is fulfilled, the fluid is defined as an exudate:
 - Pleural fluid protein/serum protein ratio greater than 0.5
 - Pleural fluid LDH/serum LDH ratio greater than 0.6
 - Pleural fluid LDH greater than two-thirds the upper limits of the laboratory's normal serum LDH (*at UCMC LDH ULN = 245*)

LDH 260

Protein <2.0

Glucose 103

Cholesterol <50

Triglyceride 81

Total cells 11,158 (RBC 11,000,

WBC 158 with 83% lymphocytes)

(1) Pleural fluid LDH/serum LDH =
 $260 / 622 = \mathbf{0.42} \rightarrow \mathbf{NO}$

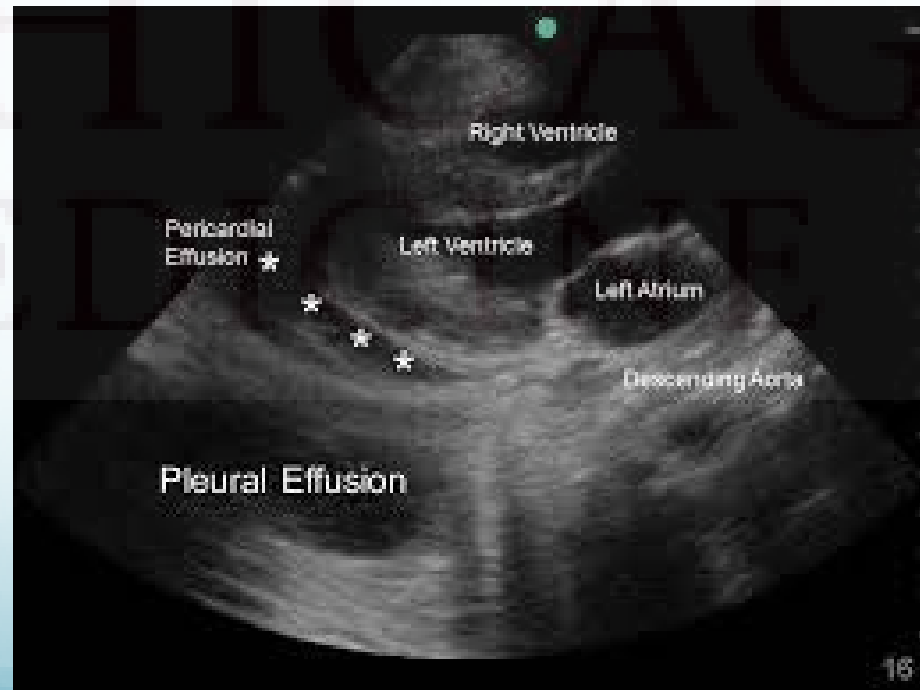
(2) Pleural fluid protein/serum
protein = $<2.0 / 4.4 = \mathbf{0.45} \rightarrow \mathbf{NO}$

(3) Pleural fluid LDH $\mathbf{260} > \mathbf{162}$ (2/3
serum LDH ULN) $\rightarrow \mathbf{YES}$

Exudate

TTE

Large bilateral pleural effusions resulting in respirophasic changes in mitral and tricuspid flow resulting in **mild hemodynamic compromise**



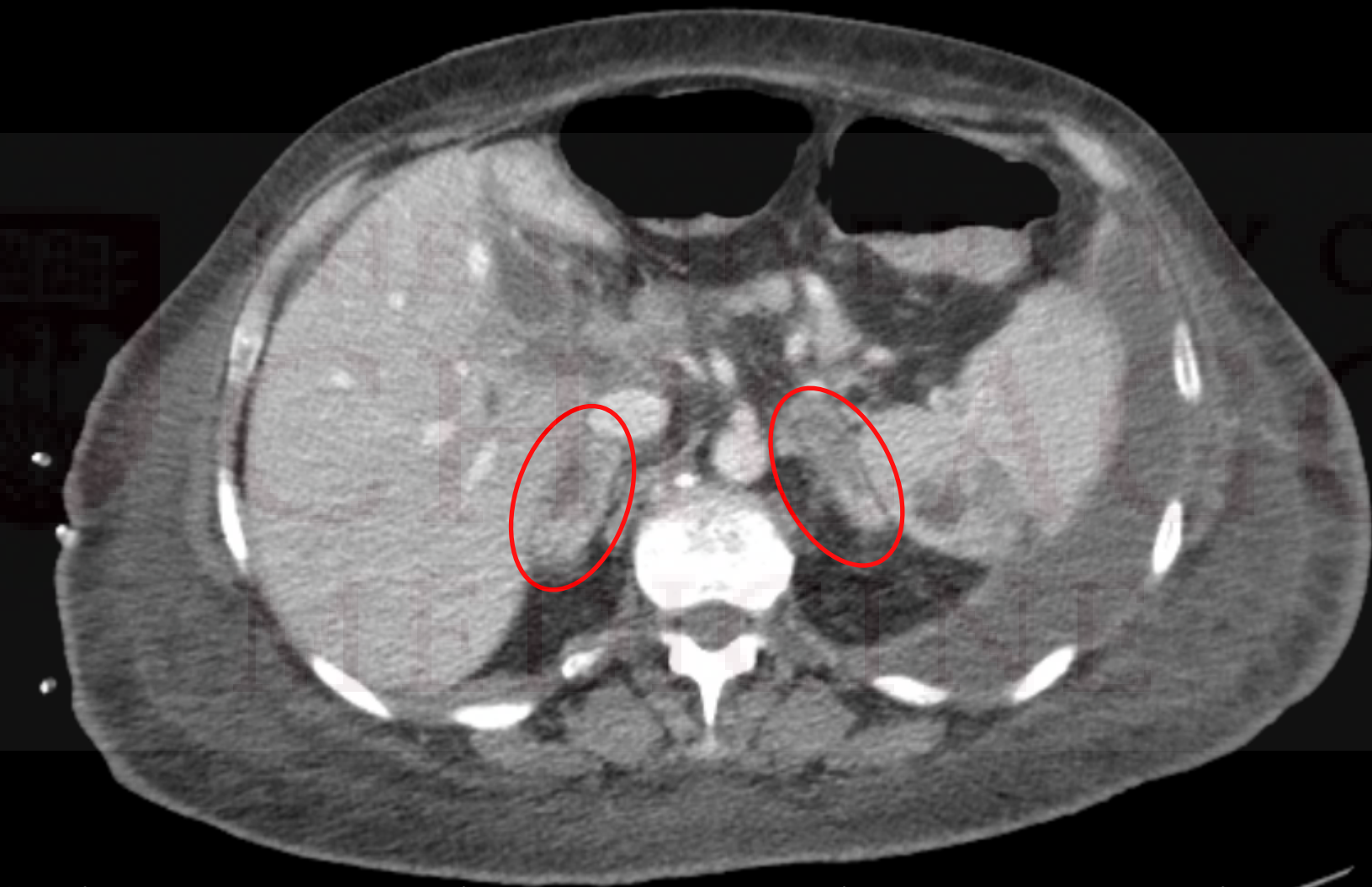
CT Chest

- Moderate to large size left and small right **pleural effusions**, with signs of loculation.
- Multiple predominantly pleural-based nodules are probably **pleural metastasis**. **Pulmonary parenchymal metastases** are probably present as well, especially in the left lower lobe. Pneumonia/pneumonitis could be contributing to the overall picture.
- There are multiple partially imaged abnormalities in the upper abdomen including **necrotic adrenal masses**, pathologic porta hepatis lymphadenopathy and abnormal thickening of the gallbladder with associated mild intrahepatic biliary dilatation. There are also **hypoattenuating lesions within the spleen and liver, likely metastasis** as well.
- Given the necrotic masses in the adrenal glands and the small heart size, please consider adrenal insufficiency as well.
- While sarcoidosis can cause pleural effusions as well as pulmonary and abdominal visceral involvement, the lack of intrathoracic lymphadenopathy would be unusual.

CT Abdomen/Pelvis

- Peripherally enhancing collection medial to the left lobe of the liver suspicious for an abscess.
- Multiple hypodense lesions in the spleen. These are of indeterminate in origin but differential diagnosis includes abscess, metastatic disease versus less likely splenic cysts.
- **Bilateral adrenal hypodense masses.** Right adrenal mass measures 3.2 x 1.7 cm image #30, series #201. Left adrenal gland mass measures 3.6 x 1.2 cm image #30, series #201.

R



OF
O

Recommendations?

- Benign or malignant?
 - CT adrenal protocol wwo
- Secreting or non-secreting?
 - Plasma metanephrines
- Causing insufficiency?
 - 8AM cortisol

Bilateral Adrenal Masses

Table 1. Bilateral adrenal lesions

Neoplasms

Malignant

Metastases

Lymphoma

Phaechromocytoma

Adrenocortical carcinoma

Neuroblastoma

Ganglioblastoma

Benign

Adenoma

Congenital adrenal hyperplasia

Macronodular adrenal hyperplasia

Infections

Tuberculous

Histoplasmosis

Blastomycosis

Parasitic cysts

Trauma

Adrenal haemorrhage

Pseudocyst

Hypoperfusion complex

Clinical presentation

- Incidental/staging
- Symptoms of catecholamine excess
- Hypercortisolism
- Abdominal pain
- Adrenal insufficiency

Bilateral Adrenal Masses

- Case series from western India 2002-2015
- 560 patients with adrenal masses, 70 were bilateral (12.5%)

Table 1 Characteristics of bilateral adrenal masses with various aetiologies.

	Pheochromocytoma	Tuberculosis	Lymphoma	Metastases	P value
Total patients: <i>n</i> (%)	28 (40%)	19 (27.1)%	7 (10%)	4 (5.7%)	–
Males: Females	13:15	15:4	6:1	3:1	0.023
Age (years) ± s.d.	33.2 ± 16.5	41.5 ± 12	48.8 ± 12.5	61.5 ± 8.3	<0.001 ^a
Range	(11–65)	(21–60)	(30–67)	(60–72)	
Duration of symptoms (months) ± s.d.	19.1 ± 18.7	18.6 ± 25.1	3 ± 2.3	5.2 ± 2.2	0.16 ^a
Range	(1–60)	(0.25–92)	(0.25–6)	(3–8)	
Presenting symptoms					
1. Hyperadrenergic spell	15 (53.5%)	0	0	0	<0.001
2. Hypocortisolism	0	18 (94.7%)	4 (57.1%)	0	<0.001 ^b
3. Abdominal pain	8 (28.5%)	1 (5.2%)	3 (42.8%)	4 (100%)	<0.001 ^c
4. Asymptomatic	5 (17.8%)	0	0	0	0.12 ^d
Biochemistry					
Hypocortisolism	0	19 (100%)	5 (71.4%)	0	
CT features					
Mean size (cm) ± s.d.	4.8 ± 2.6	2.1 ± 0.7	5.5 ± 2.0	4 ± 0.6	<0.001
Range	(1–15)	(1–4)	(2–8)	(3–5)	
1. Right-sided lesions (cm) ± s.d.	4.7 ± 2.4	2.2 ± 0.6	4.8 ± 2.1	3.9 ± 0.8	
2. Left-sided lesions (cm) ± s.d.	5 ± 2.9	2.0 ± 0.7	6.2 ± 2.2	4.2 ± 0.5	

Adrenal Protocol CT wwo

ADRENAL GLANDS: Bilateral adrenal hypodense masses, which enhance on venous imaging and increased enhancement on delayed imaging.

- Right adrenal mass measures 3.2 x 1.4 cm (301/37). **Right 25.73 HU**
- Left adrenal gland mass measures 3.4 x 1.1 cm (301/37). **Left 31.62 HU**

Imaging of Adrenal Masses

- **CT with/without contrast**

- Hounsfield units:

- **<10** very likely benign adenoma
- **>20** suggests non-adenoma (pheo, ACC, metastasis)

- Washout

- Rapid washout suggests benign adenoma (**absolute washout >50% after 10 minutes**)
- Delayed washout suggests non-adenoma (pheo, ACC, metastasis)

- **18-FDG PET**

- High uptake: adrenal hyperplasia, TB, hemorrhage, pheochromocytoma, ACC, lymphoma, metastasis
- Low uptake: adenoma, myelolipoma

Additional Endocrine Labs

- TSH 3.58
- Cortisol 20.8 (4am)
- Renin 50, Aldosterone 20

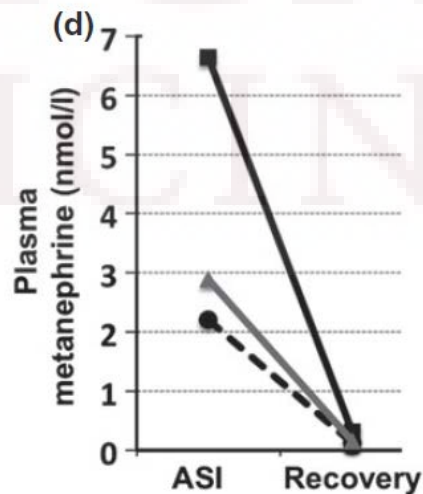
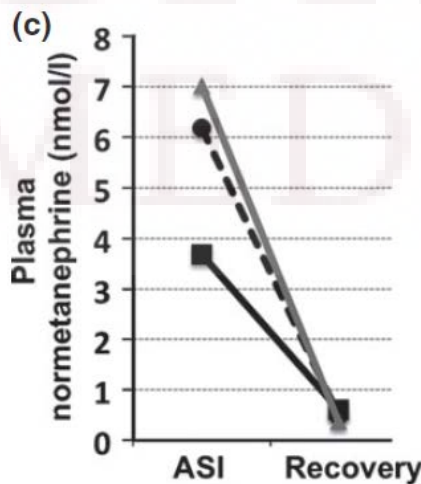
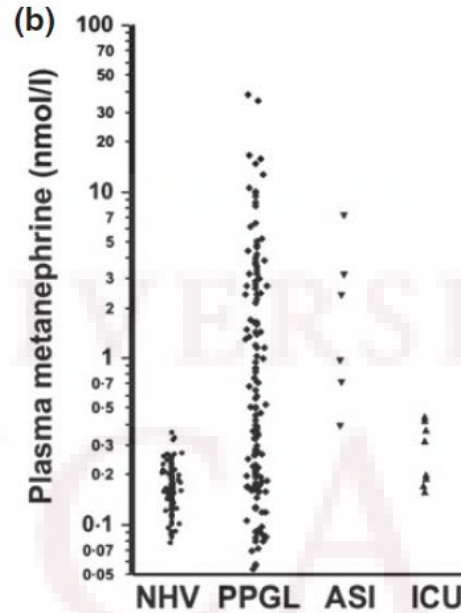
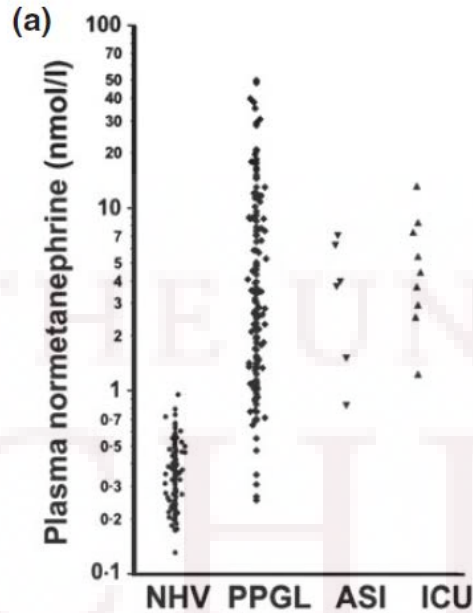
4/11/2018 2:31 PM - Interface, Lab

Component Results

Component	Value	Ref Range & Units	Status
Normetanephrine	2.7 (H)	<0.90 nmol/L	Final
Metanephrine	<0.20	<0.50 nmol/L	Final
Comment:			

Diagnosing Pheochromocytoma in Acute Illness

Measurement of plasma normetanephrine and metanephrine in LC pheochromocytoma and paraganglioma: a meta-analysis of 10 studies. *Journal of Clinical Endocrinology and Metabolism*. 2015 Sep;95(3):785-92. doi: 10.1210/clinem.2014-1211. Epub 2014 Jun 11.



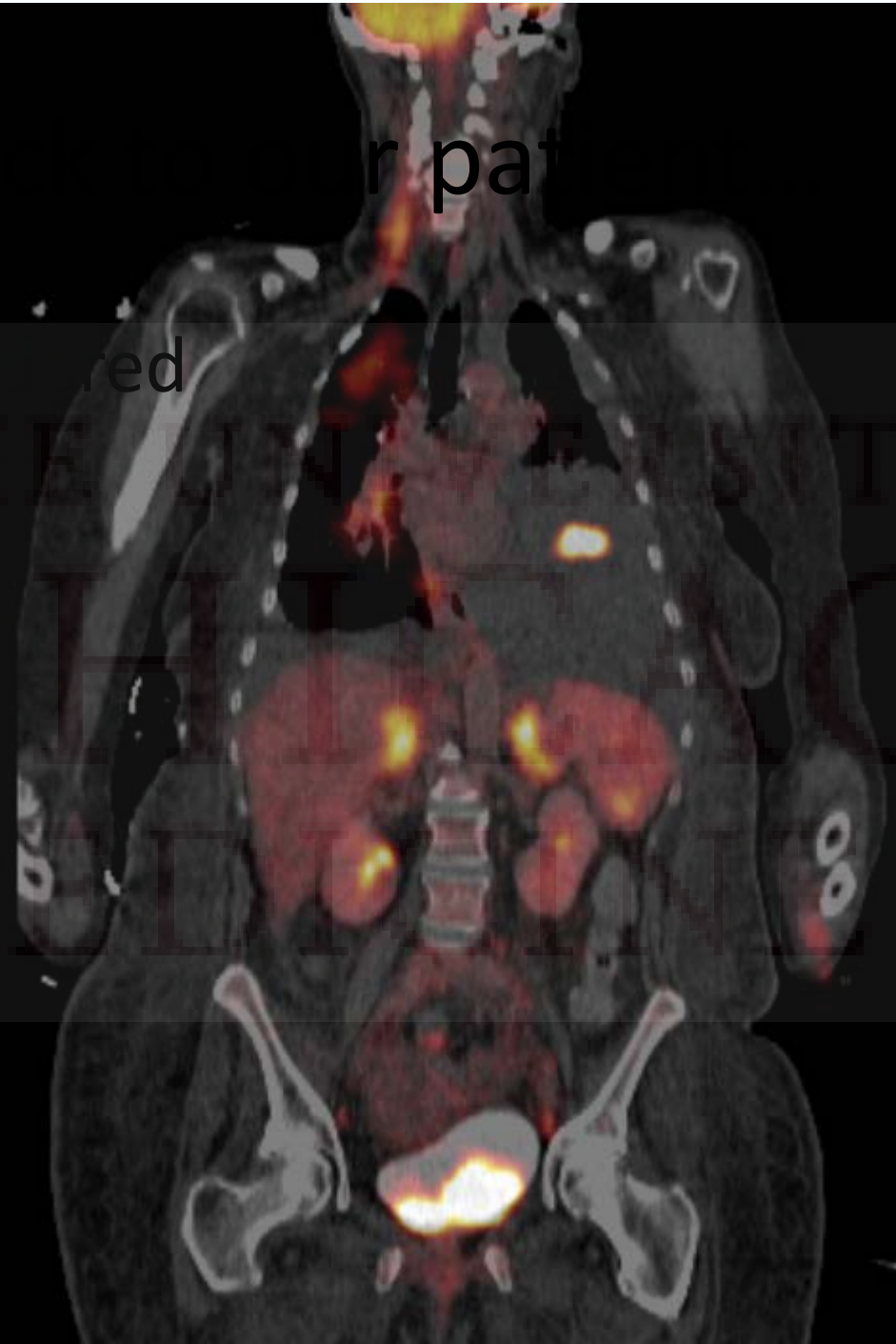
Measurement of plasma normetanephrine and metanephrine in LC pheochromocytoma and paraganglioma: a meta-analysis of 10 studies. *Journal of Clinical Endocrinology and Metabolism*. 2015 Sep;95(3):785-92. doi: 10.1210/clinem.2014-1211. Epub 2014 Jun 11.

r pat

red

R

THE UNIVERSITY OF
CHICAGO
MEDICAL CENTER



PET Whole Body

IMPRESSION:

1. Multiple hypermetabolic lung nodules and masses, and hypermetabolic lymph nodes in the neck, chest, abdomen and pelvis, as well as bilateral adrenal hypermetabolic masses, **highly suspicious for metastatic tumor. However, sarcoidosis can have similar appearance.**
2. The rim-like increased activity seen in the porta hepatis/adjacent to the gallbladder fossa, which can be due to necrotic lymph node or abscess.
3. Inflammatory groundglass opacities in both lungs.

Intense FDG uptake in the bilateral adrenal masses. The SUV max in the left adrenal mass is 8.9.

Metastatic tumours of the adrenal glands: a 30-year experience in a teaching hospital

K.-Y. Lam* and C.-Y. Lo†

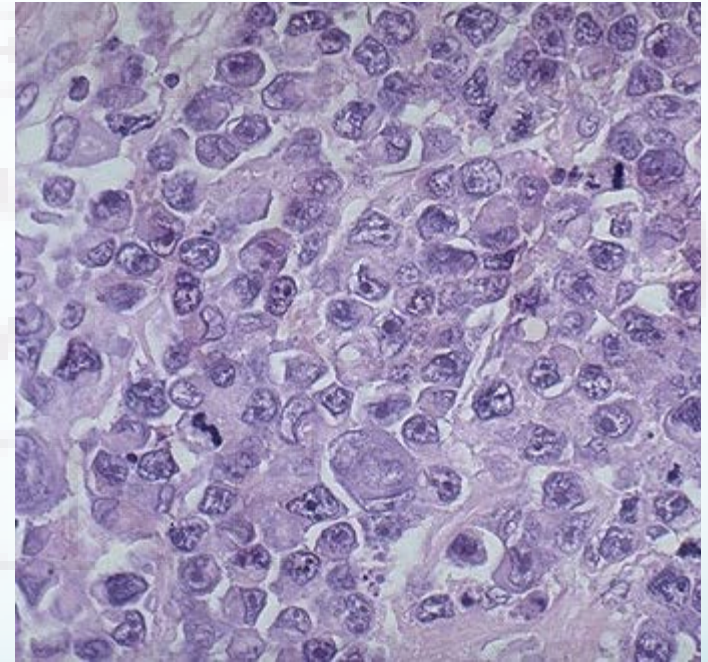
*School of Medicine, James Cook University, Townsville, Australia & †Department of Surgery, University of Hong Kong, Hong Kong, Clinical Pathology Building, Hong Kong

(Received 6 March 2001; returned for revision 20 June 2001; finally revised 12 July 2001; accepted 24 July 2001)

- Study in Hong Kong from 1971-2000
- 464 patients w/ metastatic disease in the adrenal glands
- 421 (**90%**) were carcinomas
 - Most common sites: lung (35%), stomach (14%), esophagus (12%), liver/bile ducts (10%)
- 33 (**7%**) were hematopoietic neoplasms
 - 31 lymphomas, (3 Hodgkin's, 28 NHL), 2 leukemias
- Adrenal metastases were bilateral in about half of the patients (n = 229, 49%)

Tissue is the Issue: CT-guided Lung Biopsy

- 4/18 underwent CT-guided biopsy of a right lower lobe lung mass.
- **DIAGNOSIS: Large B cell lymphoma**, BCL2 80%, Ki67 80% with T cell rich background
- Sections from the core biopsy show scattered large lymphoid cells with high nuclear cytoplasmic ratio, irregular nuclear membrane and prominent nucleoli. Numerous histiocytes and small lymphocytes are admixed with the large cells.
- Immunoperoxidase studies show that the larger cells are positive for CD20, OCT2, PAX5, CD79a, MUM1, BCL2 (80%) and negative for CD15, CD3, TCR-beta, EBER, pan cytokeratin. The tumor shows a high proliferation index (Ki 67) of 80%. CD3 immunostains highlight rich background of T lymphocytes.



Received January 10, 1983; accepted after revision March 10, 1983.

¹Department of Radiology, University of Virginia Medical Center, Charlottesville, VA 22908. Address reprint requests to M. R. Paling.

AJR 141:303-305, August 1983
0361-803X/83/1412-0303
© American Roentgen Ray Society

Adrenal Involvement in Non-Hodgkin Lymphoma

Michael R. Paling¹
Brian R. J. Williamson¹

- Retrospective analysis of 173 patients with NHL between 1978 and 1982
- Seven patients (4%) showed adrenal involvement at some point
 - 3 at initial presentation
 - 4 at tumor recurrence
- In six cases adrenal tumors resolved with treatment similar to other disease sites
- One case developed adrenal insufficiency late in course

Hospital Course

- **Hyponatremia** improved with hydration and was stable 130-135
- TTE showed **mild hemodynamic compromise** from her pleural effusions.
- Multiple RRTs, MICU evals, and CCU evals for **hypotension** which usually responded to drainage of her R pleural effusion. Drainage was gradually increased to daily and then to TID.
- Diagnosed with **LLE DVT** and started on a heparin drip
- Recurrent **atrial fibrillation** with RVR for which she was started on amiodarone.

Hospital Course, continued

- On 5/2/18 she underwent an LP and was then started on R-CHOP and intrathecal methotrexate.
- After pretreatment with benadryl and steroids she was noted to be confused and slow to respond.
- Mental status deteriorated further and she had an aspiration event with subsequent bradycardia and hypotension.
- Intubated for airway protection, transferred to ICU
- Refractory shock (4-5 pressors, high dose steroids), renal failure (CVVHD), ARDS (paralyzed, iNO)
- Made DNR, passed away on 5/5/18

References

1. Amar L, Eisenhofer G. Diagnosing pheochromocytoma/paraganglioma in a patient presenting with critical illness: biochemistry versus imaging. *Clin Endocrinol (Oxf)*. 2015 Sep;83(3):298-302. doi: 10.1111/cen.12745. Epub 2015 Mar 11. PubMed PMID: 25683095.
2. Lenders JW, Duh QY, Eisenhofer G, Gimenez-Roqueplo AP, Grebe SK, Murad MH, Naruse M, Pacak K, Young WF Jr; Endocrine Society. Pheochromocytoma and paraganglioma: an endocrine society clinical practice guideline. *J Clin Endocrinol Metab*. 2014 Jun;99(6):1915-42. doi: 10.1210/jc.2014-1498. PubMed PMID: 24893135.
3. Gupta P, Bhalla A, Sharma R. Bilateral adrenal lesions. *J Med Imaging Radiat Oncol*. 2012 Dec;56(6):636-45. doi: 10.1111/j.1754-9485.2012.02435.x. Epub 2012 Sep 27. Review. PubMed PMID: 23210583.
4. Lomte N, Bandgar T, Khare S, Jadhav S, Lila A, Goroshi M, Kasaliwal R, Khadilkar K, Shah NS. Bilateral adrenal masses: a single-centre experience. *Endocr Connect*. 2016 Mar;5(2):92-100. doi: 10.1530/EC-16-0015. Epub 2016 Apr 1. PubMed PMID: 27037294; PubMed Central PMCID: PMC5002952.
5. Nieman LK. Approach to the patient with an adrenal incidentaloma. *J Clin Endocrinol Metab*. 2010 Sep;95(9):4106-13. doi: 10.1210/jc.2010-0457. Review. PubMed PMID: 20823463; PubMed Central PMCID: PMC2936073.
6. Dong A, Cui Y, Wang Y, Zuo C, Bai Y. (18)F-FDG PET/CT of adrenal lesions. *AJR Am J Roentgenol*. 2014 Aug;203(2):245-52. doi: 10.2214/AJR.13.11793. Review. PubMed PMID: 25052555.
7. Lam KY, Lo CY. Metastatic tumours of the adrenal glands: a 30-year experience in a teaching hospital. *Clin Endocrinol (Oxf)*. 2002 Jan;56(1):95-101. Review. PubMed PMID: 11849252.
8. Paling MR, Williamson BR. Adrenal involvement in non-Hodgkin lymphoma. *AJR Am J Roentgenol*. 1983 Aug;141(2):303-5. PubMed PMID: 6603123.