66-year-old woman with a pituitary mass

Anoopa Koshy, M.D.

THE UNIVERSITY OF CHICAGO MEDICINE

HPI

- 66 yo Taiwanese F with hx of seizure disorder was seen in NSG clinic after recent MRI revealed a pituitary mass (presenting symptoms-decreased vision, headaches)
- Has a hx of seizure disorder for 7 years and has been on carbamazepine
- Oct. 2011, her neurologist checked her MRI and discovered a suprasellar mass, ~1.5 in. diameter encroaching the optic chiasm

THE UNIVERSITY OF CHICAGO MEDICINE

HPI continued…

- baseline poor vision in left eye-hx of epiretinal membrane surgery in left eye in 2007
- Best corrected acuity is 20/30 in rt. eye and 20/200 in lt. eye
- Automated visual fields per Optho revealed “a right temporal hemi-defect with mild nasal changes and left eye is diffusely abnormal”
- Ophtho recommended surgery

HPI continued…

- Seen by Dr. Lesniak in NSG clinic in 1/2012 who recommended a craniotomy to allow optimal decompression of the optic chiasm

- Ordered labs to evaluate pituitary function

Prolactin- 7.69 (4.8-23.3 ng/ml)
FSH- 43.8 miU/ml
LH- 24.3 miU/ml
ACTH- 63 pg/ml (<52 pg/ml)
IGF1- 172 (69-200 ng/ml)
TSH- 1.56 (0.3-4 mcU/ml)
Ft4- 0.81 (0.9-1.7 ng/dl)

THE UNIVERSITY OF CHICAGO MEDICINE

HPI continued…

- Underwent lt. craniotomy on 1/31
- Immediately after surgery, patient complains of blindness in both eyes
- STAT head CT shows "blood products within resection cavity"
- Emergently taken back to the OR 1/31 for re-exploration, removal of blood contents and to free optic nerve

HPI continued….

- Ophtho consulted and vision continued to improve during hospital course
- Started on dexamethasone 6 mg q6h after surgery (tapered down by ~1 mg a day over 5 days until tapered off)
- Patient scheduled to leave for rehab on Monday 2/6, Endo consulted for evaluation

THE UNIVERSITY OF CHICAGO MEDICINE

Past Medical History

- Seizure disorder (dx 7 years ago)
- Diet controlled diabetes
- Hypertension
- Newly diagnosed pituitary mass
- Hx of cataract surgery in both eyes
- Hx of epiretinal membrane surgery in left eye in 2007 with poor vision in left eye at baseline

THE UNIVERSITY OF CHICAGO MEDICINE

Home meds:

Carbamazepine 200 mg TID

Diovan 80 mg daily

Hospital Meds:

Brimondine eye drops

Carbamazepine 200 mg TID

Valsartan 80 mg po daily

Novolog 1-5 unit sliding scale

Social Hx, Family Hx, ROS

- Social Hx
- - Married and lives with her husband, who is a retired Ob-gyn in NW Indiana.
- -Has 2 grown daughters.
- -Originally from Taiwan
- -Not working
- -Denies smoking, etoh, drugs

- Family Hx- no hx of pituitary tumors, both her parents died of "natural causes." Both daughters are healthy.

- ROS-

-Denies any weight changes
-vision has been poor for years
-infrequent headaches.
-denies galactorrhea
-no changes in ring size
-denies muscle weakness

THE UNIVERSITY OF CHICAGO MEDICINE

Physical Exam

- VS: 97^0 F, 118/59, RR 18, 98% on RA, 5'2'', 139 lbs

Gen: NAD

Head: s/p craniotomy, stitches in place

Eyes: ptosis in R>L, right cranial nerve III palsy documented per ophtho

Neck: no thyromegaly

Heart: +S1/S2, no murmurs

Lungs: CTA b/l

Abdomen: soft, ntnd, +bs

Extremities: no c/c/e

Neuro: Alert and oriented x 3, no focal deficits, muscle strength normal, right cranial nerve III palsy, other cranial nerves intact

THE UNIVERSITY OF CHICAGO MEDICINE

Labs

- 138 | 104 | 22 /120
  4.1 | 22 |0.4 \

A1c- 6.5

12.1 \ 10.7 /311
/ 33 \

THE UNIVERSITY OF CHICAGO MEDICINE

Serum sodium and Urine output

-NaCl 2 gm TID
-750 ml/day fluid restriction

Tolvaptan 15 mg

Na	137	145	149	145	141	138	128	124	121	124	132	140
	1/30	1/31	2/1	2/2	2/3	2/4	2/5	2/6	2/7	2/8	2/9	2/10
Uop	1L	2.9L	2.3L	2.7L	2.4L	500cc	100cc	500cc	1.3L	1.1L	1.5L	1.2L

THE UNIVERSITY OF CHICAGO MEDICINE

Additional labs from 2/5

- Plasma Osm-263 (289-308 mOsm/kg)
- Urine Osm- 776 (500-800 mOsm/kg)
- Urine Na- 159 mEq/L

THE UNIVERSITY OF CHICAGO MEDICINE

SIADH

- Plasma osm <270 mosmol/kg H_2O
- Inappropriate urine concentration
  - Uosm > 100 mosmol/kg H_2O
- Euvolemic
- Elevated urine Na >40 mmol/L

THE UNIVERSITY OF CHICAGO MEDICINE

SIADH and pituitary surgery

- Hyponatremia is a late common complication of pituitary surgery, occurring in 21-35% of cases
- Major cause is inappropriate ADH release from injured pituitary gland
- Fall in serum sodium is most severe on the 6-7th post-operative day

Triphasic Response

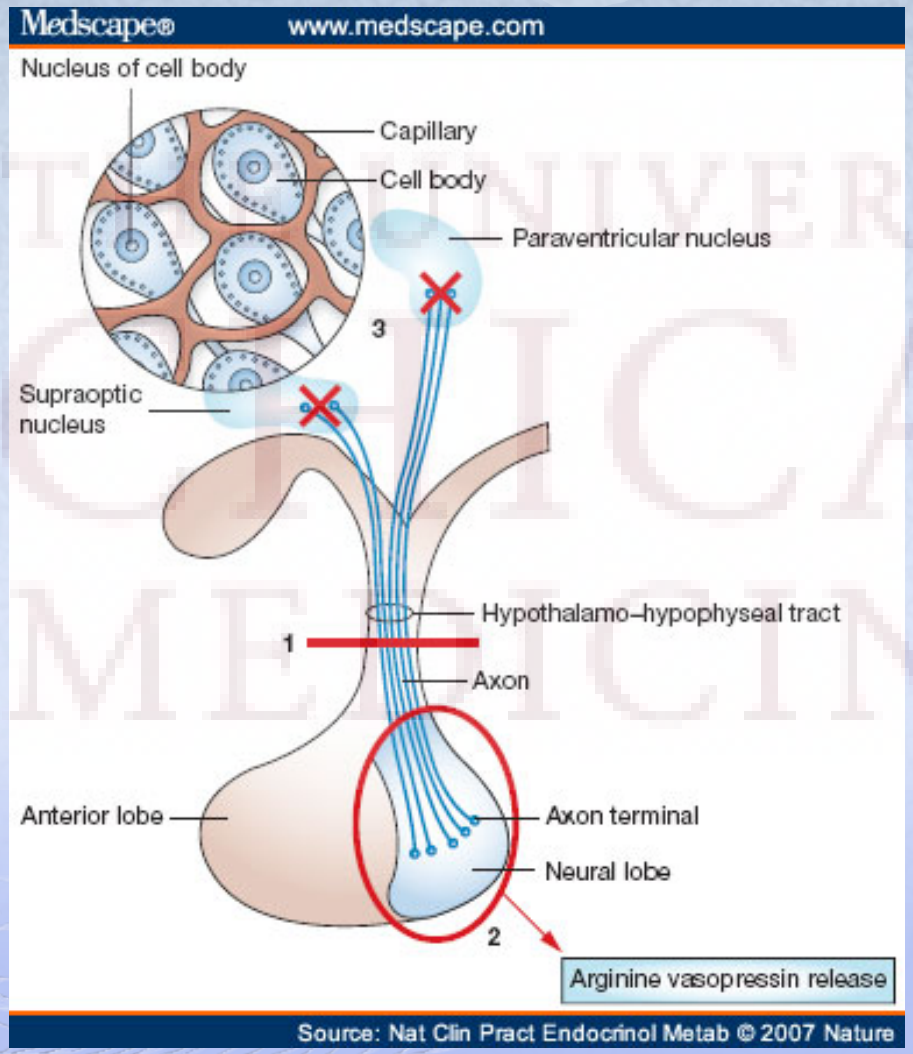

Triphasic Response

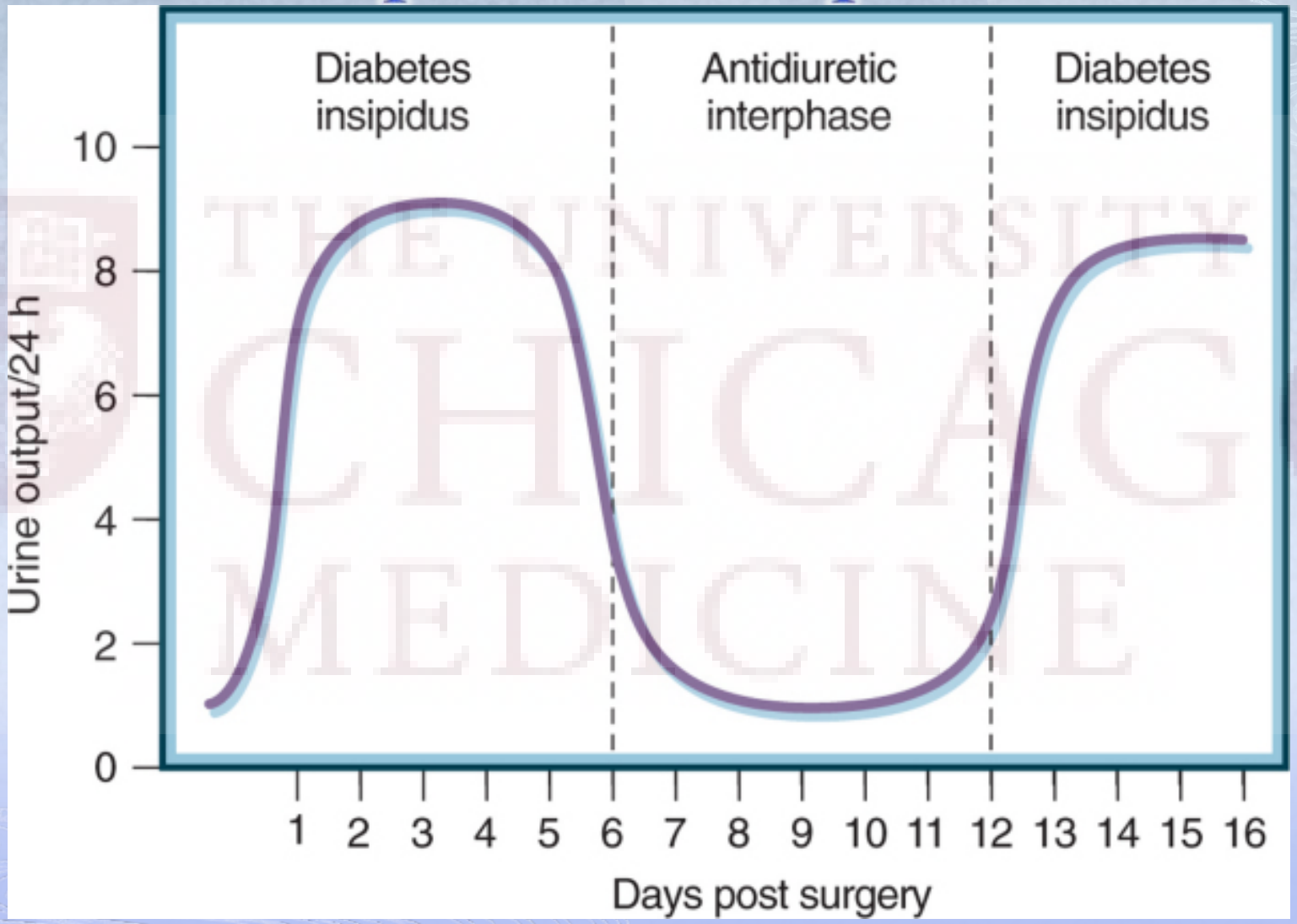

Williams Textbook of Endocrinology, 12th ed.

Tolvaptan

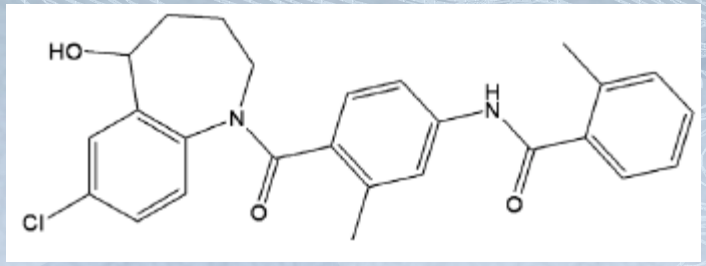

- An arginine vasopressin (AVP) receptor antagonist with affinity for AVP receptor subtypes V2 and V1a.

- Antagonism of the V2 receptor promotes excretion of free water, resulting in net fluid loss, increased urine output, decreased urine osmolality, and subsequent restoration of serum Na levels.

Tolvaptan

- Tolvaptan was approved by the U.S. Food and Drug Administration on May 19, 2009.
- Should only be used in a hospital setting where serum Na can be monitored closely
- Too rapid correction of hyponatremia (e.g., ≥ 12 mEq/L/24 hours) can cause central pontine myelinolysis resulting in dysarthria, mutism, dysphagia, lethargy, spastic quadriparesis, seizures, coma and death.
- Patient should be allowed to drink when thirsty while on the medication

THE UNIVERSITY OF CHICAGO MEDICINE

Carbamazepine and SIADH

- Acts by stimulating release of ADH and potentiates its action by promoting reabsorption of water
- Has been used as an alternative treatment for DI
- Development of SIADH has been reported in the literature since 1973
- Risk of carbamazepine-induced hyponatremia has been associated with increased age (>30 years)
- Patients with additional risk factors (ie. Pituitary surgery) could be at increased risk of developing SIADH

THE UNIVERSITY OF CHICAGO MEDICINE

Hospital Course

- Patient's sodium stabilized after receiving 1 dose of tolvaptan
- Her vision also improved.
- Sent to rehab with salt tablets and fluid restriction
- Serum sodium to be monitored daily while at rehab and NaCl tabs to be tapered
- Outpatient Endo f/u and Ophtho f/u.

THE UNIVERSITY OF CHICAGO MEDICINE

Take Home Points

- Typical triphasic response of urine volume follows sectioning of the pituitary stalk induced by surgery .
- The 1st phase of diabetes insipidus occurs immediately postoperatively and continues to day 6.
- The second phase of antidiuresis occurs from day 7-day 12.
- The third phase is the reocurrence of diabetes insipidus on day 13.
- Carbamazepine can increase sensitivity to ADH.
- Tolvaptan is an effective treatment of post-operative SIADH.

THE UNIVERSITY OF CHICAGO MEDICINE

References

- Sherlock M, Thompson CJ. The syndrome of inappropriate antidiuretic hormone: current and future management options. Eur J Endocrinol. 2010 Jun;162 Suppl 1:S13-8. Epub 2010 Feb 17. Review. PubMed PMID: 20164215.
- Gold PW, Robertson GL, Ballenger JC, Kaye W, Chen J, Rubinow DR, Goodwin FK, Post RM. Carbamazepine diminishes the sensitivity of the plasma arginine vasopressin response to osmotic stimulation. J Clin Endocrinol Metab. 1983;57(5):952.
- Kamiyama T, Iseki K, Kawazoe N, Takishita S, Fukiyama K . Carbamazepine-induced hyponatremia in a patient with partial central diabetes insipidus. Nephron. 1993;64(1):142.
- Sachdeo RC, Wasserstein A, Mesenbrink PJ, D'Souza J . Effects of oxcarbazepine on sodium concentration and water handling. Ann Neurol. 2002;51(5):613.
- Palm C, Pistrosch F, Herbrig K, Gross P. Vasopressin antagonists as aquaretic agents for the treatment of hyponatremia. Am J Med. 2006 Jul;119(7 Suppl 1):S87-92. Review. PubMed PMID: 16843091.
- Vaghasiya RP, Devita MV, Michelis MF. Serum and urine responses to the aquaretic agent tolvaptan in hospitalized hyponatremic patients. Int Urol Nephrol. 2011 May 24. [Epub ahead of print] PubMed PMID: 21607553.

THE UNIVERSITY OF CHICAGO MEDICINE